

Sh. Gupta
Library
Sh. Gopal

Compendium on

All India

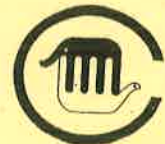Zoo Veterinarian Conference

on 3rd Feb. 2004



36/1/06

Sponsored by
Central Zoo Authority



Organised by
Lucknow Zoological Gardens



**Compendium
on
All India
Zoo Veterinarian Conference
on 3rd Feb. 2004**

**Sponsored by
Central Zoo Authority
New Delhi**

361 / mib

**Organised by
Lucknow Zoological Gardens
Lucknow**

Published for Director, Lucknow Zoological Gardens, Lucknow
February 2004

Cover Photo : Tiger (*Panthera tigris tigris*) in Lucknow Zoo

Photo : Suresh Chaudhari (Ornithologist and Wildlife Photographer)

Designed & Produced by : Ibex Advertising, Lucknow

Printed at Prakash Packagers, Lucknow



Surjit Kaur Sandhu

I.A.S.

Principal Secretary

FOREST DEPARTMENT

601, Babu Bhawan, Lucknow

Tel.: 0522- 2238669 (O)

2235881 (Fax)

It is a pleasure and an honour to come to the All India Zoo Veterinarian Conference, organized by Lucknow Zoo and funded by the Central Zoo Authority, New Delhi. I have been told that Zoo Veterinarians from around 22 different states are attending this conference. Officers In charge of different Indian Veterinary Colleges have come here as resource persons to throw light on establishing linkages between Veterinary Institutions and Indian Zoos towards better health management of the animals.

It is very essential to keep our selves up dated with the latest techniques pertaining to restraint and translocation of wild animals. The basic aim for transfer of species from captive to captive conditions, wild to captive and wild to wild conditions is for the conservation, education, research and enrichment of wildlife diversity. Methods of capture, handling and transfer of animals needs very careful handling. Chemical immobilization of wild animals by expert Veterinarians facilitates their capture without involving much manpower and saves time. You are aware of the latest equipments for administration of drugs from remote distance in to the animal body.

Similarly, translocation of the animals, right from their capturing, loading, crating, transportation, unloading and release is a massive task. Translocation may lead to physical injuries and stress in animals and a Zoo veterinarian has to be very careful with these live animals.

Most of the Zoo Veterinarians, who have come here, must be well versed with the subject and others may gain by their experiences.

We are proud that Central Zoo Authority, New Delhi has selected Lucknow for the conference and I am sure that all of you will be greatly benefited at the outset.

(Surjit Kaur Sandhu)

Principal Secretary (Forests)

Govt. of U.P., Lucknow



Kaushalendra Prasad

**Principal Chief Conservator of forests
Uttar Pradesh**

17 Rana Pratap Marg, Lucknow -226001

Phone : 0522-2206168

Respected Principal Secretary (Forest), Govt. of U.P., Mrs. Surjeet Kaur Sandhu, distinguished guests, Zoo Veterinarians from all over India, ladies and gentlemen. I am pleased to be present here for the All India Zoo Veterinarian Conference, which is being organized for the first time in Lucknow. On behalf of the Forest Dept., I welcome all our distinguished guests who have come here from more than 22 states to this historical capital of Uttar Pradesh. The topic to be shared by all of you today is developing skills in restraint and translocation of wild animals.

Chemical capture of wild animals is not an easy task. There is a likelihood of failure when a new chemical or technique is used. Since Veterinarians do not routinely use some of the modern immobilizing drugs, necessary expertise must be sought from knowledgeable sources. I'm sure that organizing such conferences where experts assemble from all over India, are very beneficial.

The main aim of transfer of wild animals within the Zoo or to other Zoos is done, as you all know, for improving the gene pool, or for breeding purposes or for providing mates to the single species. Wild animals are also restrained for medical and research purposes. It is very relevant for the Zoos in the present scenario as a majority of the exchange proposals within different Zoos revolve around this aspect.

Skillful handling is required for restraining the wild animals, either physically or mechanically or chemically. If not handled with care, the animals may be hurt & may come under stress.

I have been told that renowned scientists from various Veterinary colleges have also come here to participate in the conference. Your expert suggestions will be very useful in providing linkages between different Veterinary institutions and Zoos towards better health management.

(Kaushalendra Prasad)

Principal Chief Conservator of forests

Uttar Pradesh, Lucknow



Mohammad Ahsan
Chief Wildlife Warden, U.P.
17 Rana Pratap Marg, Lucknow
Tel.: 0522-2206584

Respected Principal Secretary Forest, Govt. of U.P. Ms. Surjeet Kaur Sandhu, Principal Chief Conservator of Forests, U.P. Sri Kaushalendra Prasad Saheb, distinguished delegates from various corners of the country, officers from the U.P. Forest department, colleagues from the media, ladies and gentlemen, I feel honoured to be here in this workshop on "Developing Skills in Restraint and Translocation of Animals in Zoos". I take it as a privilege to say a few words on this occasion.

Zoos world over have come a long way from just being the collection of animals or menageries to the serious scientific institutions. If some of them have not, it is high time they do and play a major role in the arena of conservation.

Though the collection of animals was always patronized in one form or the other by the Indian kings and Mahrajas, yet many European countries- especially after the Egyptian campaign of Napoleon- like France and Germany pioneered in designing and establishing the zoos, the way we know them today. In the middle of nineteenth century a number of major European cities vied with each other in establishing zoos, especially, once the gates of Africa and Latin America were open to them. The mega fauna of wondrous Africa so much fascinated the Europeans that zoo business became a major commercial activity and animal trade flourished in a big way in the latter part of the nineteenth century. Trapping parties were sent to Africa and other exotic places to fetch the animals in huge numbers. There came the professional companies that operated on international scale and could supply any number of animals on a price. Since the animals were in plenty, no body cared even if they died in any number during trapping and transport operations. Sometimes the entire consignment perished during long transport and transshipment. Faulty packing and cursory handling of shipment resulted into serious injuries to the animals and many of them sometimes died on way to their destination. On the top of that many an animal did not survive in extreme and alien climatic conditions.

Wanton destruction of natural resources, their rapid depletion and extinction of many species forced to change our attitude towards zoos. They started playing major role in conservation, breeding of endangered species, research and education. They can no longer be treated as places of excitement and sources of cheap entertainment- not even the hub of cultural activities of the town. They are much more than that. In an age when there is a serious crisis of survival before many species and the number within the community is becoming critical, the role of zoos becomes pivotal in our strategy for conservation of nature and natural resources.

About a century back we plunged into the mistake of thinking that our natural resources were unlimited. We could take any number or any quantity from the nature. But history proved us wrong. Many a species became extinct or critically endangered in our own

the last decade, however, rapid development of injectable anesthetics in human and veterinary medicine plus improved delivery system have benefited everyone involved with animal capture. There have been many individual reports and publications on restraint, but no contemporary, single publication has incorporated these latest developments under one cover.

This conference is a chance for the zoo veterinarian, zoo manager and scientists to come together on one platform to emit expertise and share knowledge about the latest rules, advancement, researches and publications of new development in restraint and translocation.



(Eva Sharma)

Director

Lucknow Zoological Gardens

Lucknow

Contents

	<i>Page no.</i>
1. Rescue Operation of Injured Wild tiger at Rajiv Gandhi National Park and its Rehabilitation at Sri Chamarajendra Zoological Gardens, Mysore - <i>Dr. S.S.M.S. Khadri, Dr. S.C. Valandikar, Kumar Pushkar</i>	- 1
2. Chemical restraining of a Gaur (<i>Bos gaurus</i>) for treatment of Actinomycosis at Sri Chamarajendra Zoological Gardens, Mysore - <i>Dr. S.C. Valandikar, Dr. S.S.M.S. Khadri</i>	- 4
3. Tranquilization & Tethering of Musth Indian Elephant "Ganesha" at Sri Chamarajendra Zoological Gardens, Mysore, A case Report - <i>Dr. S.C. Valandikar, Dr. S.S.M.S. Khadri</i>	- 6
4. Immobilization & Translocation of 40 Sambars carried out at Sri Chamarajendra Zoological Gardens, Mysore - <i>Dr. S.S.M.S. Khadri, Dr. S.C. Valandikar, Kumar Pushkar</i>	- 8
5. Management of Tibial Fracture in African Elephant calf at Mysore Zoo - <i>Dr. S.S.M.S. Khadri, Dr. S.C. Valandikar, Kumar Pushkar</i>	- 10
6. Mass Tranquilisation of Spotted deer (<i>Axis axis</i>) and their shifting to Arabittu Reserve forest - <i>Dr. S.S.M.S. Khadri, Dr. S.C. Valandikar, Kumar Pushkar</i>	- 12
7. Mass Tranquilization of Black Bucks (<i>Antelope cervicapra</i>) and their Translocation and their Translocation carried out at Sri Chamarajendra Zoological Gardens, Mysore - <i>Dr. S.S.M.S. Khadri, Dr. S.C. Valandikar, Kumar Pushkar</i>	- 15
8. Tranquilization and Translocation of animals in Tata Zoo, Jamshedpur - <i>Dr. M. Palit</i>	- 17
9. Tranquilization of Male Sloth Bear - <i>Srinivasa Murthy G, Dilip Kumar Das, NL Raghava, Markandaiah KB</i>	- 21
10. Hand Rearing of Emu Chicks at Arignar Anna Zoological Park, Vandalur - <i>K. Senthilkumar, K.Divaki, R. Thirumurugan, Rathan Nazrullah Khan</i>	- 23
11. Experiences on capture and Translocation of Elephants and Rhinoceros from field - <i>Dr. Kushal Konwar sarma</i>	- 24
12. Centre for Wildlife Conservation and disease Surveillance - <i>Dr.D.Swarup</i>	- 26
13. Enrichment of Technical Liaisonship between Zoos & Veterinary Research Institution - <i>Dr. M.G. Jayathangaraj</i>	- 30
14. Resource persons who attended the conference on 03.02.04	- 32
15. List of Veterinarians who attended the conference on 03.02.04	- 33
16. List of Birds reported from Lucknow Zoological Gardens	- 36



**Rescue
Operation of
Injured Wild
Tiger at
Rajiv Gandhi
National Park
and its
Rehabilitation
at
Sri
Chamarajendra
Zoological
Gardens,
Mysore**



Dr. S.S.M.S. Khadri

Veterinary Officer, Mysore Zoo

Dr. S.C. Valandikar

Asst. Director, Zoo Hospital, Mysore Zoo

Kumar Pushkar I.F.S.

Executive Director, Mysore Zoo

Introduction :

A wild male tiger aged about 8 years, was seriously injured in its left fore limb by a Jaw trap laid by the poachers. Thanks to the Video footage taken by a Jungle Lodges Wildlife Tourist, which helped Forest Department Staff to conduct intensive combing operation and rescue the injured tiger, which was later shifted to Sri Chamarajendra Zoological Gardens, Mysore, to provide necessary treatment for its rehabilitation.

Rescue Operation :

On 31st May 2002 staff of Forest Department of D.B. Kuppe range noticed a wild tiger having an injury in its left fore limb & it was found limping. The video footage taken by wildlife tourist, was telecast in various news channels, clearly showing Jaw trap in the left fore limb. The Principal Chief Conservator of Forests (wildlife Preservation) Mr. Chakrabarthy, I.F.S., mobilized all the concerned staff, wildlife veterinarians & kumki elephants etc., to start the rescue operation. It was a challenging job to locate the injured male tiger because of the dense under growth of Lantana and other vegetation. On 2nd July 2002, Conservator of Forests, Sri Annur Reddy was able to track the injured tiger in the evening, but could not dart the tranquilizer as it was getting dark. On the 6th of June, 2002 morning, tribal trackers were able to find the den where wild injured tiger had taken shelter in Mastigudi section of D.B. Kuppe range. The den was ideally selected by the injured tiger and it was located very close to back water of kabini reservoir. Perhaps the tiger was surviving on water, as it is impossible to make kill due to serious injury in its fore limb.

The mouth of the den measured 2½ feet in width and it was radiating down to about 5 feet, which lead to a chamber sufficient to accommodate adult tiger. The mouth of the den was closed by spreading a net and observation was made. Though it was aggressive, it did not move on approaching the dens mouth. For safety reasons, Iron grill gate was used and placed over the net. This facilitated to look into the semi dark environment of the den under the torch light. We could see the head and the right limb. The injured left limb was covered. The animal was disturbed with the help of a pole and it moved exposing the left limb. It had a serious injury infested with maggots. Meanwhile two holes were



drilled from above into the den to allow more light for observation. The rescue cage was positioned and attached to the mouth of the cage and crackers were busted. Though it was agitated, it resisted to move. Water was poured in to the drilled holes to flush the tiger out in to the rescue cage but it didn't work. It was getting dark. Therefore it was decided to tranquilize the animal. Dr. Khadri darted the tranquilizer to the right shoulder under the light of the torch. The symptoms of sedation was noticed within 10 minutes and then the tiger was noosed through shoulder & the neck and gently pulled into the rescue cage. It was around 8.45 p.m. the cage was slowly shifted with the help of the staff and loaded on the transporting truck. The wound was washed with antiseptic and examined. The trap had caused serious injury, severing all the toes along with the paw. A open septic wound contaminated with soil and infested with maggots could be seen. First aid treatment was provided. As the Tiger was fasting, since almost 6 days without getting any food due to the injury we offered 5 kgs of chicken, which it ate completely. The Conservator of forests, Madikeri circle Sri. Annur Reddy, I.F.S., & Deputy Conservator of Forests, Hunsur Division Sri. Annaiah, I.F.S., decided to shift the injured tiger to Sri Chamarajendra Zoological Gardens, Mysore for further treatment. The tiger was shifted to Mysore Zoo on the same night & reached the zoo at 3.00 a.m.

Treatment Attended At Mysore Zoo

On the 7th of June morning, it was tranquilized using Ketamine Hcl 600 mg & Xylazine 100 mg in combination injected manually as the animal was kept in the squeeze cage. Induction time 15 minutes, under sedation the injured limb was examined thoroughly. The wound was disinfected, maggots & dead tissue were removed. The wound was flushed with metronidazole & anti septic wokadine solution. Inflammatory condition of the affected limb was noticed & the animal had the fever, body temperature being

104.50 F. It was decided to treat the animal with antibiotics, analgesic & anti-inflammatory agents to control the infection, before taking the surgical amputation of the affected limb. The infection was brought under control by giving Megamycin (amoxacylin) + (cloxacycin) 1.5 gms twice a day I/M along with voveran (diclofenac sodium) 1mg per kg body weight I/M two consecutive injections in two days was provided.

On the 3rd day, the body temperature returned to normal 100.50F & inflammation of the limb also got reduced. Daily dressing of the wound was attended. On 14th June, it was decided to amputate the affected limb at the lower end shaft of radio-ulna bones.

Amputation of the Effected limb

A team of doctors Dr. Vasanth Shetty, Professor, Dept. of Surgery, Dr. Ranganath Asst. Professor, Dept of Surgery, Veterinary College, Hebbal, Bangalore, Dr. Shadakashar Murthy & the zoo veterinarians Dr. S.C. Valandikar, Asst. Director & Dr. S. S.M.S Khadri, Veterinary Officer attended the surgery of the injured wild tiger. The tiger was sedated using Ketamine Hcl 700 mg & Xylazine Hcl 200 mg (estimated weight of the tiger 150 kgs). Under sedation it was shifted to the operation theatre. Mobile x-ray unit was mobilized from Mysore Race Club equine dispensary & radiographs of the affected limb was taken before conducting the operation.

Zoo vets Dr. S.C. Valandikar & Dr. S.S.M.S Khadri monitored the anesthesia, pulse, respirations & body temperature, while Dr. Vasanth Shetty, Associate Professor conducted amputation of the injured limb at radio-ulna at lower end of the shaft. Supplementary dose of tranquilizer was necessary, ketamine 100 mg & xylazine 25 mg was injected to prolong the sedation for completing the surgical operation. It took about 2 hours & 10 minutes to complete the amputation of the affected left fore limb. Noticing the recovery symptom like twitching of ears &



palpebral & pupillary reflexes, the tiger was immediately shifted from operation theatre to squeeze cage. For revival procedure, Antagozil 2.5 ml & Doxapram 2 ml was given I/M. After about 20 minutes, the animal recovered from sedation & took to the sternal recumbency. Postoperative care & treatment was continued & it took about two weeks for healing of the surgical wound & later another two weeks for its complete recovery. The animal is keeping good health & its appetite is normal. 10 kg of beef, 1 kg chicken & about ½ kg liver is being provided (liver twice in a week). Hygienic environment is provided all around the squeeze cage to avoid fleas, which may cause maggots infestation.

Rehabilitation

The rescued wild tiger is presently housed at Mysore Zoo and can be exhibited after creating

necessary exhibit facility for educational purpose to bring awareness among the zoo visitors to convey the information of the danger being caused by the poaching of wild animals for their skin & bones. The jaw trap used for the attempted poaching of this wild tiger will also be displayed in front of the exhibit for it may convey the message of the seriousness that this species is going towards extinction unless and otherwise protection & conservation measures are seriously taken.

Acknowledgement :

We sincerely thank the team of surgeons, Dr Vasanth Shetty, Dr. Ranganath & Dr. Shadakshar Murthy of Veterinary college Bangalore & Govt. Poly clinic Mysore, for their co-operation in surgical intervention in amputation of fore limb of Royal Bengal Tiger.





Chemical Restraining of a Gaur (*Bos gaurus*) for treatment of Actinomycosis at Sri Chamarajendra Zoological Gardens, Mysore



Dr. S.C. Valandikar
Asst. Director, Zoo Hospital
Sri Chamarajendra Zoological
Gardens, Mysore

Dr. S.S.M.S. Khadri
Veterinary Officer, Zoo Hospital
Sri Chamarajendra Zoological
Gardens, Mysore

Introduction :

Actinomycosis or lumpy jaw commonly noticed in cattle population, is also found among the wild gaurs and other herbivores. A case has been noticed in an adult male gaur aged about 6 years, robust and well built in its health condition and a proven sire, which has bred four calves in 2003.

A Case Study :

The keeper of the enclosure reported swelling on the right side of the mandibular region. The animal was kept under observation and tentative diagnosis was made as actinomycosis (lumpy jaw). The swelling started growing in its size and became a large lump without involving tongue in a period of 30-40 days. Tetracycline was given @ 4grams per day for seven days. But no desired response was noticed. Hence it was decided to dart the animal on 24-1-2004. Necessary preparations were made to mobilize sodium iodide for the treatment purpose.

Chemical Restraining :

The animal was darted using short-range projectile pistol, 5ml dart syringe was selected and red charge ejection was used. Combination of drugs Xylazine Hcl 60mg and Immobilon 1ml(2.24mg/ml) mixed together and darted to the neck region. After 6 minutes of darting, ataxia with head downwards appeared.. No excitement and the animal came down to sternal recumbency at the 10th minute. The animal was manually approached and shifted to holding room. Necessary treatment with sodium iodide 20gram powder mixed with 50ml of distil water, was given subcutaneously in three sites and long acting oxytetracycline Hcl 200mg/ml, 30ml was injected deep I/M. the lump was opened, drained the yellow pus and collected the material for laboratory examination. The lab report confirmed the diagnosis of actinomycosis showing filamentus branching type.

Revival Procedure :

The animal was revived with Revivon 1ml I/M, Romaverse 5ml I/M, and cold water was poured over its body to cool down the body temperature (1020F - normal being 1010F). The animal became alert, showed eye pupillary reflexes, ear, tail reflexes and



movement of both fore limb and hind limb noticed and stood to its limbs after 10 minutes of giving Revivon & Romaverse.

Result :

On 3rd & 4th day of treatment we could appreciate regression of mandibular swelling to almost 70%. Tetracycline Hcl 75 grams powder per day mixed with feed and given, and aqueous solution of sodium iodide 20 grams mixed with 50 ml of distilled water given subcutaneously every week and further treatment is due.

Conclusion :


The case of actinomycosis has been recorded for the first time in an adult gaur {Bos gaurus} in Mysore Zoo. The response to the treatment is good and it needs surgical intervention to open the abscess and to treat the case under observation.

Acknowledgement :

Thanks are due to our Executive Director, Sri Kumar Pushkar IFS for the encouragement and providing facility to attend the case.



Tranquilization & Tethering of Musth Indian Elephant “Ganesha” at Sri Chamarajendra Zoological Gardens, Mysore, A Case Report



Dr. S.C. Valandikar

*Asst. Director, Zoo Hospital,
Sri Chamarajendra Zoological
Gardens, Mysore*

Dr. S.S.M.S. Khadri

*Veterinary Officer, Zoo Hospital,
Sri Chamarajendra Zoological
Gardens, Mysore*

Introduction :

In Musth, the male adult elephant pose a big problem to mahout and Zoo Managers, due to their aggressive behaviour. They cause severe injuries stampede and even death to near by attendants like animal keepers & mahout. There are many such incidences where elephants went wrong and became uncontrollable. Therefore it is very important to control aggressive elephants by chemical tranquilization /immobilization.

A Case study :

Ganesha, an Indian elephant aged 25 years, presented by the Manthralaya Math to this zoo is a robust and well built animal, weighing around 3 ½ tons, had become uncontrollable and aggressive on the morning of 25-01-2004. He even mated the female elephant Padmavathi, may be in oestrous. The animal keeper reported of its aggressive behaviour and attack on him, who escaped narrowly. Observation was made, both temporal glands had the swelling and secretion was found oozing out. Therefore it was decided to tranquilize/immobilize the elephant for tethering purpose.

Methodology :

At 09:45 a.m., prepared the dart syringe with Xylazine Hcl 3.5ml & darted the animal using shortrange projectile pistol. After about 20mins of induction time, mild relaxation of tail, trunk & ear was noticed, but still animal was alert and could not manually approach it. Second dart was made at 10:30 a.m., with the supplementary dose of Xylazine 1.5ml and allowed further 20 minutes. Movements of tail, trunk & ear diminished and snoring could be heard. On manual approach still it was showing reflexes and was showing its trunk though in a relaxed manner. At this juncture it was decided to use Immobilon 0.3ml at a very low dosage (Etorphine Hcl 60mg & Acepromazine maleate 3mg). At 10:50 a.m., prepared the dart syringe with Immobilon and darted the animal. After about 7 minutes of induction time loud snoring could be heard animal was totally stand still and no movements of tail, trunk & ears was found. It was then possible to approach the animal at 10:57 a.m. and applied the necessary chains in both hind & fore limbs and tethered the animal. At 11 a.m. it came down to right



lateral recumbency. Removed all the dart syringe from the body and applied betadine solution and injected menomycine forte in to all the three dart syringe sites to avoid the infection into the darting site. After securing the animal revival procedure was started by giving Revivon 0.5 ml. I/V and Romaverse(Yohimbine Hcl)5 ml I/M & 5 ml. I/ V. Liberal water was poured over the body of the animal to bring down the temperature(1000F), normal being 980 F. Pupillary reflexes and trunk movement noticed after 7 minutes of giving Revivon & Romaverse. The animal got up to its limbs after 30 minutes.

Conclusion :

Captive elephants under musth conditions in Zoo situation can best be attended by darting the drug in combination of Xylazine Hcl and immobilized for getting desired results for necessary tethering the elephant to avoid the risk from musth elephants to the keepers, mahout and other zoo workers. Xylazine as the base drug and appropriately selecting Etorphine Hcl with Acepromazine at low level gives wonderful results. In the present case 500mg of Xylazine

and 0.3ml (60mg) of Immobilon made the tusker to snore in the standing posture and manual approach was possible and chaining the feet was attended. Later the animal came down to sternal recumbency and then to lateral. Revived the animal using Revivon 0.5ml I/V and Romaverse 5ml I/M and 5ml I/V revived within 30 minutes.

Acknowledgement :

Thanks are due to the Executive Director, Sri. Kumar Pushkar I.F.S. for providing opportunity to immobilize the musth elephant for chaining purpose.

Reference :

1. Harthoorn A.M. 1976 The chemical capture of animals-A guide to the Chemical Restraint wild and captive animals. Bailliere Tindall, London.
2. S.S.M.S. Khadri and M.K. Appayya- 1992- Chemical capture of wild elephants and their translocation carried out in Karnataka state-The Asian Elephant, Ecology , Biology, Diseases Conservation and Management- Kerala Agricultural University.





Immobilization & Translocation of 40 Sambars carried out at Sri Chamarajendra Zoological Gardens, Mysore



Dr. S.S.M.S Khadri
Veterinary Officer

Dr. S.C. Valandikar
Asst. Director

Kumar Pushkar, I.F.S
Executive Director

Sri Chamarajendra Zoological
Gardens, Mysore

Introduction :

- Mysore Zoo is exhibiting different species of deer & antelopes.
- It includes endangered species like Brow antlered deer, Swamp deer, Muntjack & Four horned antelope.
- The climatic conditions at Mysore and the enclosure environment are conducive for the successful breeding of deer and antelopes.
- The population of the Deer and Antelopes increased tremendously over a period of time.
- This resulted in competition for feeding and breeding & space within the enclosure.

Methodology :

- Chemical capture & translocation of Sambars.
- 40 Immobilisations of which 32 for translocation & 8 for shifting was conducted.
- Drug used – Immobilon (Etorphine Hcl 2.24 mg/ml + Acetylpromazine 10 mg/ml)
- Estimated body weight
 - a. Adult male 150-200 Kgs.
 - b. Adult female 100-150 Kgs.
- Drug dosage – 2.264 mg/animal (1.1 ml of the drug).

Equipment used :

- Dist inject long range projectile gun.
- Dist inject short range projectile pistol.
- Dart syringe barrel size 3ml/5ml.
- Syringe charge 1-5ml.
- Ejection charge Blue (1-12m) & Red(10-12m) for pistol.
- Ejection charge Brown(20-35m) & White (30-50m) for gun.

Injection site & Drug action :

- Neck – Shoulder – Rump site.
- Induction time 7 –10 min (mean – 7 min).



- Immobilisation symptoms.
- Isolation from the herd. – 1st minute
- In coordination of limbs – 3rd minute
- Ataxia. - 4th minute
- Closing of eye lids. - 5th minute
- Sternal recumbency with neck up. – 5th – 7th minute
- Lateral recumbency with groaning. –7th –10th minute
- Stage of complete Immobilisation.

Approach to the immobilised animal :

- Approach the animal when it is completely down after the induction time of 10th minute.
- Use water to wet the body of the animal in case of hyperthermia.
- Use stature for shifting the animal to transporting vehicle.
- Keep the neck & head of the animal at higher level to avoid aspiration of ruminal content.

Revival procedure :

- After shifting of the animal to the transporting vehicle check for the vital function of the body.
- Revive the animal with Diprinorphine Hcl 5mg I/M or I/V depending upon the condition of the animal.
- Use life saving drugs only when required.
- Recovery time 5-7 min for gaining righting reflexes.

Precautions for Immobilisation procedure :

- Do not give roughages a day earlier.
- Do not feed concentrates in the morning.
- Do not dart advanced pregnant female.
- Do not use Etorphine in very young animals.
- Avoid darting stags in velvet.

- Remove stagnation of water inside the enclosure.
- Do not under dose the animal.
- Approach only when they are completely immobilized.
- Have sufficient staff for shifting the animal to vehicle.
- Vehicle cabin should be fully covered to create darkness and to avoid animals jumping out.

Translocation :

- Maintain 40 km speed.
- Most of the animals take sternal recumbency during the journey.
- Provide hay bedding in the transporting vehicle.
- Do not park the vehicle in the sun.
- Make observation of the animal intermittently.
- Take low traffic roads.
- Carry life saving & revival drugs and first aid kit.

Release in Herbivores Safari, B.N.P., Bangalore :

- Take the vehicle to a ramp for the convenient release of animals.
- Avoid causing stress – allow time to get the animals out.

References :

1. The Capture and care of wild animals-1973 by Dr. E.Young.
2. The chemical capture of animals- 1976 by A.M. Harthoorn.
3. Zoo & wild animal medicine-1999 by Fowler & Miller
4. Zoo medicine – 1976 by Dr. Heinz-Georg Klos & E.M.Lang





Management of Tibial Fracture in African Elephant calf at Mysore Zoo



Dr. S.S.M.S Khadri
Veterinary Officer

Dr. S.C. Valandikar
Asst. Director

Kumar Pushkar, I.F.S
Executive Director

Sri Chamarajendra Zoological
Gardens, Mysore

Introduction :

Fractures in wild animals in captivity are observed due to fall, infighting among the species or accidental etc., Mysore Zoo has both Asiatic & African Elephants, kept in separate enclosures side by side. We have one male and one female adult African Elephant, which gave birth to a male Elephant calf in the year 1994. The African Elephant calf, which was with Indian Elephant calves, was recently introduced to the Enclosure of African Elephants as one species.

A Case Report :

An African Elephant Calf named Richi aged about 9 years & weighing 1.5 tons born in Mysore Zoo, had an accidental fracture of left hind limb on 11th Sept 2002 causing simple Tibial fracture at middle portion of the tibia due to mounting of male adult African Elephant weighing about 4 tons who was noticed in the musth was trying to mount on the female but the calf intervened between them and the tusker mounted on the calf, which the calf could not bear the weight and had fallen down, receiving knee injury and fracture.

Diagnosis :

The calf showed lameness, pain & inability to use the limb & to sustain weight. Subsequently, swelling & crepitus at the place of fracture was observed. Examination & handling of the fractured portion showed tenderness & confirmed as a case of fracture of tibia.

Treatment :

Immediately, 21 rolls of Plaster of Paris (Gypsona) of 15cms cast was applied under mild sedation of Xylazine 100 mg I/m. The calf was tied in the enclosure without allowing to move away from the place. After about one & half month the leg showed malformation of callous, due to bending of the cast, causing bending of the leg inside. Therefore, it was decided to break the soft callous and reunite the broken Tibia by stretching the leg on 24th Nov 2002 under Immobilisation and to take necessary X-Ray before recasting with poly fiber Dura cast.

On 24th Nov 2002 at 7:30 AM, injected Immobilon 1.3 ml (2.912 mg) intramuscularly. After induction time of 10 minutes,



the animal slept on right lateral recumbency with profound sleep. Following observation were made :

At 8:10 AM :

1. Pulse 40 / Minute.
2. Respiration 8 / Minute.
3. Conjunctiva Pink.

Therefore we cut off and removed the Gypsona Plaster of Paris cast. Exposed the affected limb to the mobile X-ray brought there and developed the film. Clinically examined the limb, which showed hard callous formed at the site of fracture and could not be broken by hammer because of hardness and it left as such and decided to put another fresh Poly fiber Dura cast bandage.

At 8:40 AM again we examined the animal and noticed

1. Pulse 58 / Minute.
2. Respiration 7 / Minute.
3. Conjunctiva Pink.

Applied tightly 8rolls of poly fiber Dura cast of 4" X 6" wide by dipping in warm water and wrapped around the fractured part over the padded cotton on the entire fractured portion forming a thick layer over it. The plaster bandage applied spirally and tightly. The Dura cast hardened quickly within minutes and remained as hard as possible. The animal revived with Revivon (Diprinorphine 1.8 ml [5.4 mg]) and it got up within 10-12 minutes. The following treatment was rendered to the ailing Elephant calf.

1. Voveran : 12ml Im. on first day.
2. Optineuron : 12ml Im. on first day.
3. Proxyvet (Diclofenac Sodium and

Paracetamol Bolus-vet): 4 boluses orally through food, twice a day given for a week to reduce oedema & pain.

4. Vimerol : 5ml once daily for one month
5. Ostocalcium syrup: 30 ml twice a day for the entire period of healing for about 3 months as a Calcium supplement required for healing and callous formation.

Conclusion:

The movements of the animal restricted for further 1 ½ to 2 months. The animal was stall-fed and stationary to avoid breakage of callous. The animal assisted to rise and put weight on 14th Dec 2002. The calf was taken for a trial walk. No doubt, hard callus had formed, but because of non-alliance of fractured tibia properly as seen in the X-Ray film, the bending of the calf noticed. We have removed the Duracast on 31st Dec 2002. Slight limping of the left hind leg was still noticed. The calf rests on the ground intermittently, but it will not affect its normal life in walking. This is the first case of simple fracture in African Elephant and also Indian Elephant in Mysore Zoo, which was managed and treated successfully. The calf is leading its normal life of regular feeding and exercise in the enclosure with its parents.

Reference :

1. The Capture and care of wild animals-1973 by Dr. E.Young.
2. The chemical capture of animals- 1976 by A.M. Harthoorn.
3. Zoo & wild animal medicine-1999 by Fowler & Miller.
4. Zoo medicine – 1976 by Dr. Heinz-Georg Klos & E.M.Lang.





Mass Tranquilisation of Spotted deer (*Axis axis*) and their shifting to Arabitittu Reserve Forest



Dr. S.S.M.S Khadri
Veterinary Officer

Dr. S.C. Valandikar
Asst. Director

Kumar Pushkar, I.F.S
Executive Director

Sri Chamarajendra Zoological
Gardens, Mysore

Introduction :

Sri Chamarajendra Zoological Gardens, Mysore is housing more than 375 spotted deers in 3 different enclosures. As they are prolific breeders, their population greatly increased over a period of time. Because of the over population, the infighting among the stags during the rutting season and competition for feeding and space resulted in increase in the mortality rate of the captive Spotted deer. To control their population, we had taken up castration of few selected dominant stags using Burdizzo castrator, under sedation. But it is not possible to control the prolific breeding of spotted deer in a high-density enclosure by this method. Hence a thought was given for the mass tranquilization of spotted deer and their shifting to isolated patch of Reserve forest, Arabittu, in the out skirts of the Mysore city.

The over population of Spotted Deer, apart from causing stress and increasing the mortality due to infighting trauma, is very expensive to maintain them in captivity.

Methodology :

Tranquilization of deer for treatment, crating and other procedures is generally carried out using Ketamine HCl in combination with Xylazine. For mass shifting of 300 spotted deer, the regular procedure of darting each animal with said drug combination is cumbersome and very expensive. Each dart syringe along with said drug combination costs about Rs.2000.00.

The mass tranquilization of spotted deer using Diazepam (Valium 10 mg tab) was adopted at Sri Chamarajendra Zoological Gardens, Mysore. On trial basis, under control measures Diazepam was given 0.85 grams to 2 grams along with the food for each spotted deer (Harthoorn A.M. - (1976)). It was observed that Diazepam 2 grams brings ideal sedation, which allows manual restraining on approach. The symptoms of sedation could be noticed up to 36 hours and animals recover on their own. It was decided to take up field trials using Diazepam, at the rate of 2grams per spotted deer for achieving desired degree of sedation for shifting.

On 14th Nov 2002, Diazepam (valium 10mg tab) X 2000 tabs was mixed in five kgs of concentrate feed and made in to 10 equal parts and kept separately in a holding area. Six spotted deer 1:5



consumed the full quantity of the medicated food in the holding room. Symptoms of sedation like ataxia could be noticed after 45 minutes. After about 4 hours in coordination of limbs, drowsiness, half closed eyelids with bending of neck was noticed. Finally the deer could come down on the lateral recumbency after about six hours. Two of the female deer showed insufficient sedation, may be because they had taken partial quantity of the medicated food, and showed little resistance on manual approach. The said deer were given Ketamine HCl 1ml (100 mg) intramuscularly to achieve desired sedation. All the sedated deer were safely taken to the transporting truck and shifted to Arabittu reserve forest.

On 15th Nov 2002, it was decided to feed medicated food in the afternoon around 4 PM to achieve desired degree of sedation by next day morning, which allows manual restraining without causing stress and strain to the animals. Eleven spotted deer were taken to the holding room and given medicated food at the rate of 2 gram Diazepam per animal. Next day morning (16th Nov 2002) at 7:30 AM observation was made. All the deer were showing good degree of sedation and allowed manual approach without any excitement. All the eleven (3:8) spotted deer were secured manually and taken to the transporting truck and shifted safely to Arabithittu Reserve forest.

The Arabithittu reserve forest has free ranging leopards, which unfortunately had the field day to attack six of the spotted deer, which were still not completely recovered from the sedation. As it had been noticed during the controlled trials that the sedation with Diazepam could continue even up to 36 hours. Hence the deer shifted under sedation can be taken to the holding area for at least 3 days and then they can be released to the free ranging habitat to avoid unnecessary attack by the carnivore animals.

After making necessary arrangements at the release point, mass tranquilization and translocation of Spotted Deer was started on 24th August 2003. So far we have translocated 181 Spotted Deers to Arabbi Tittu Reserve Forest. The operation was highly successful and the deers, which were shifted, are well settled in the Arabbi Tittu Reserve Forest. The mortality during procedure is mainly due to infighting trauma, which is around 5%.

Precautions :

- Benzodiazepines (Diazepam) brings drowsiness, stupor, ataxia and hypothermia.
- The affect of the Diazepam can last for 24 – 36 hours.
- Diazepam have a very high therapeutic index, even 5 – 10 times the therapeutic doses do not produce significant CNS depression, fatalities are rare.

Sl. no.	Date	Species	M	F	U	Total	Dosage (Vallium 10mg) tabs
1	25-Aug-03	Deer Spotted	2	13	0	15	2250
2	28-Aug-03	Deer Spotted	4	10	0	14	3000
3	30-Aug-03	Deer Spotted	2	11	0	13	2250
4	01-Sep-03	Deer Spotted	3	14	0	17	2625
5	09-Sep-03	Deer Spotted	7	7	0	14	3000
6	11-Sep-03	Deer Spotted	3	13	0	16	3300
7	14-Sep-03	Deer Spotted	5	11	0	16	3300
8	16-Sep-03	Deer Spotted	6	15	0	21	3650
9	18-Sep-03	Deer Spotted	5	14	0	19	3800
10	12-Oct-03	Deer Spotted	6	13	0	19	4000
			43	121	0	164	

- Diazepam 2g / animal produces ideal sedation for manual handling, if animal consumes more than the therapeutic index even to the extent of 5 times the normal dose, it is well tolerated and does not result in fatality.
- The action of the drug is delayed because the deer are ruminant animals.



Conclusion :

Mass tranquilization of the spotted deer using Diazepam is cost effective method to shift surplus population of spotted deer with out causing stress, strain, excitement and injuries to the animals. The methodology adopted at Sri Chamarajendra Zoological Gardens, Mysore has given a very successful beginning, in shifting 181 spotted deer to isolated patch of reserve forest of Arabithittu. Less than 5% mortality has been recorded during the translocation operation. The mass sedation using Diazepam can be safely employed in various Zoos, safaris and deer parks for the safe shifting of surplus stock of spotted deer in the country.

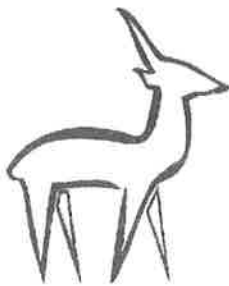Reference :

1. Dr. Young .E (1973) - The Capture and care of wild animals, South Africa Nature foundation
(Affiliated to World Wildlife Fund), Pretoria South Africa
2. Harthoorn A.M. - (1976)- The comical capture of animals- A Guide to the Chemical Restraint of Wild and Captive Animals-Bailliere Tindall, London.
3. Fowler & Miller (1999) -Zoo & Wild Animal Medicine.
4. Dr. Heinz-Georg Klos & E.M.Lang -(1976)- Zoo medicine.





**Mass
Tranquilization
of Black Bucks
(*Antelope
cervicapra*) and
their
Translocation
carried out at
Sri
Chamarajendra
Zoological
Gardens,
Mysore**



Dr. S.S.M.S Khadri
Veterinary Officer

Dr. S.C. Valandikar
Asst. Director

Kumar Pushkar, I.F.S
Executive Director

Sri Chamarajendra Zoological
Gardens, Mysore

Introduction:

Sri Chamarajendra Zoological Gardens, Mysore is housing more than 75 Black Bucks in 2 different enclosures. As they are prolific breeders, their population greatly increased over a period of time. Because of the over population, the infighting among the males during the mating season and competition for feeding and space resulted in increase in the mortality rate of the captive Black Bucks. To control their population we had taken up castration of few selected dominant males using Burdizo castrator, under sedation. But it is not possible to control the prolific breeding of Black Buck in a high-density enclosure by this method. Hence a thought was given for the mass tranquilization of Black Bucks and their shifting to herbivores safari at Bannerghatta National Park, Bangalore.

The over population of Black Buck, apart from causing stress and increasing the mortality due to infighting trauma, is very expensive to maintain them in captivity.

A Case Report :

Tranquilization of antelopes for treatment, crating and other procedures is generally carried out using Ketamine Hcl. For mass shifting of 25 Black Bucks the regular procedure of darting each animal with said drug is cumbersome and very expensive. Each dart syringe along with said drug combination costs about Rs. 2000.

On 13th October 2003 at 5p.m. the mass tranquilization of Black Buck using Diazepam (Valium 10mg tab) was attended at Sri Chamarajendra Zoological Gardens, Mysore, Diazepam 10mg tabs X 65(650mg per adult Black Buck) was given along with the food for each Black Buck (Harthoorn A.M. - (1976)). It was observed that Diazepam 650mg brings ideal sedation, which allows manual restraining on approach.

On 14th October 2003, sedated Black bucks were shifted to transporting vehicles, which was fully covered and inside environment was kept semi dark. The translocation journey took about 4 ½ hours to reach herbivores safari Bannerghatta National Park. All the Black Bucks were safely released into the holding area and necessary treatment was provided for any minor injury. The Diazepam sedation lasted for about 36 hours and animals



regained their righting reflexes and started moving.

Precautions :

- Benzodiazepines (Diazepam) brings drowsiness, stupor, ataxia and hypothermia.
- The affect of the Diazepam can last for 24 – 36 hours.
- Diazepam have a very high therapeutic index, even 5 – 10 times the therapeutic doses do not produce significant CNS depression, fatalities are rare.
- Diazepam 650mg/animal produces ideal sedation for manual handling, if animal consumes more than the therapeutic index even to the extent of 5 times the normal dose, it is well tolerated and does not result in fatality.
- The action of the drug is delayed because the antelopes are ruminant animals.

Conclusion :

Mass tranquilization of the Black Buck using Diazepam is cost effective method to shift surplus population of Black Buck with out causing stress, strain, excitement and injuries to the animals. The methodology adopted at Sri Chamarajendra Zoological Gardens, Mysore has given a very

successful beginning, in shifting 25 Black Bucks to herbivorous Safari of Bannerghatta National Park, Bangalore. Less than 0.04% mortality has been recorded during the translocation operation due to Hypothermia as it had slept in stagnant rainwater. The mass sedation using Diazepam can be safely employed in various Zoos for the safe shifting of surplus stock of Black Buck in the country.


Reference :

1. Dr. Young E. (1973) - The Capture and care of wild animals, South Africa Nature foundation(Affiliated to World Wildlife Fund), Pretoria South Africa
2. Harthoorn A.M. - (1976)- The comical capture of animals- A Guide to the Chemical Restraint of Wild and Captive Animals-Bailliere Tindall, London.
3. S.S.M.S. Khadri ,S.C. Valandikar & Kumar Pushkar I.F.S – 2003- Mass Tranquilisation of Spotted deer (*Axis axis*) and their shifting to Arabittu reserve forest- Myfoerst, September, 2003 Vol.39(3) Page Nos.217-219
4. Fowler & Miller (1999) -Zoo & Wild Animal Medicine.
5. Dr. Heinz-Georg Klos & E.M.Lang –(1976)- Zoo medicine.





Tranquilization and Translocation of animals in Tata Zoo, Jamshedpur



Dr. M.Palit

Translocation of Hippo male from National Zoological Park, New Delhi to Tata Zoo, during Jan. 96

Hippopotamus male, sub-adult was translocated from National Zoological Park New Delhi to Tata Steel Zoological Park, Jamshedpur, Jharkhand by truck during Jan, 96 in a special folding type of Steel transportation box. (Design as under)

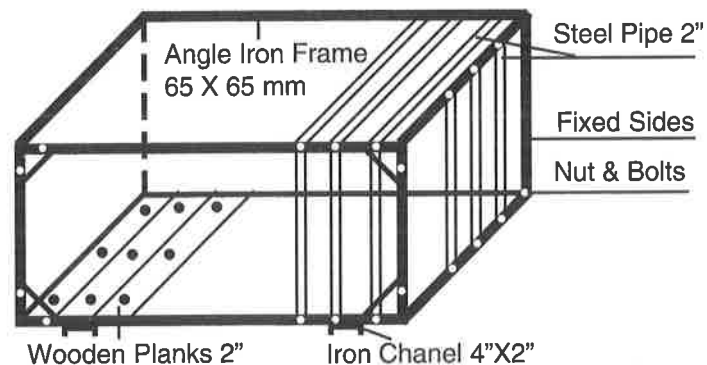
The transportation box was fixed into the hippo enclosure and the food was placed inside the box daily keeping one side open and one side close. All animals were allowed to take food from that box. After a lapse of one week the selected male was trapped by closing the back gaps.

A 200 litre capacity water tank, dry ration such as wheat bran, black gram, oilcake, procured on the way to feed the hippo.

The animal was sprinkled with water during the day time every 2-3 hour during the journey. The animal was found standing and sitting during the journey. the speed of vehicle was maintained slow and late night halt was given due to heavy fog.

- The animal was caged on 20 Jan. 96 at 2.00 pm.
- The transport box was loaded on the truck by crane at 5.00 pm.
- Departure from Delhi - 8.00 pm on 20 Jan.96.
- Arrival at Jamshedpur - 11.00 am on 23 Jan. 96.
- Route was Delhi-Kanpur-Allahabad-Varanasi-Sasaram-Hazaribag-Ranchi-Jamshedpur.

The animal was unloaded by crane inside the Hippo enclosure itself and released soon.



Folding type Hippo Transportation Box (Size-9'X5'X5')



Blackbuck translocation from IVRI, Izat Nagar, Bareilly during March 96

2:4 Blackbuck were translocated from IVRI, Bareilly to Jamshedpur by truck during March 96.

The animal were captured from big enclosure using tranquillising gun (Xylazine and ketamin Hcl mixture 1:1 ratio 0.5 ml-1.00 ml l/m to each animal, 100 mg/ml concentration) at 2.00 pm was given.

All the animals were crated separately in transportation boxes and all animals allowed to revive inside the box and then loaded on truck.

Departure from Bareilly - 7.00 pm on 25 Mar.96
Arrival at Jamshedpur - 4.00 pm on 28 Mar. 96

The route was Bareilly-Sitapur-Lucknow-Varanasi-Shasaram-Barhi-Ranchi-Jamshedpur.

The animals were fed with soaked gram, Wheat bran, Green fodder and tree leaf during the journey. Special care was taken on drinking water which was added with Herbal antistress syrup (Zee tress-Indian Herbs, Antistress formula- Allembic) and multiple electrolyte powder (Vitosil-Brihans Lab)

Translocation of Sloth Bear adult from Assam State Zoo, Guahati to Tata Zoo, Jamshedpur by truck during the Nov, 95.

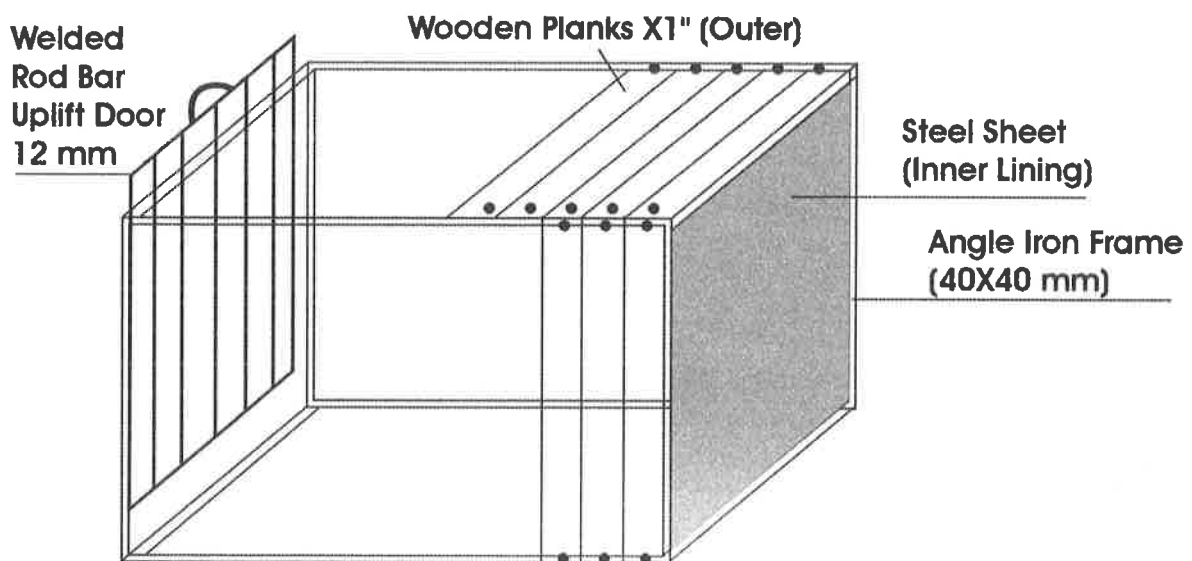
The animal was caged in specially designed transportation box made of angle iron frame with steel iron sheet on inner lining and wooden plank fixed on outer surface (Design of the cage given below) on 13-11-95 at 2 pm and was loaded on truck 7.00 pm on 13-11-95.

The bear was fed with milk (Pasteurised packed milk) and sliced bread, Banana, Cucumber and plenty of water along with oral rehydration powder (Vitosil-Brihans Lab Electral powder) during the journey.

The accompanying animals on the vehicle were Hog deers-4 and Barking deers-6.

Departure from Guahati - 6.00 am on 14-11-95
Arrival at Jamshedpur - 11.00 am on 17-11-95

The route was Assam-Siliguri-Dalkola-Katihar-Barouni-Kadoroma- Hazaribag-Ranchi-Jamshedpur.



Bear Transportation Box (Size 3'6" X 3' X 3')



Translocation of Hog deers from Assam State Zoo, Guahati to Tata Steel Zoological Park, Jamshedpur by truck during Nov. 96

The animal were immobilised from enclosure by using xylazine and Ketamine Hcl 100 mg concentration each 1:1 mixing ratio, 1.00 ml- 1.5 ml l/M by a dart gun and caged in wooden transportation box at 3.00 pm on 13-11-95. The animals were allowed for revival in the box, feed and water were also kept in the box. The boxes were loaded on the truck at 9.00 pm on 13-11-95.

Departure from Guahati - 6.00 am on 14-11-95

Arrival at Jamshedpur - 11.00 am on 17-11-95

Translocation of Camel male sub adult from Alipur Zoological Park, Kolkata to Tata Zoo, Jamshedpur during March 99

The animal was immobilised using xylazin and Ketamine Hcl mixture 1:1 ratio (4.00 ml l/M, 100 mg/ml concentration each) at 2.00 pm. The animal was loaded on the truck at 3.00 manually, the limbs were tied with cotton rope in sitting posture. The animal was found revived partially at 6.00 pm. The animal was allowed to take small quantity of food and water before journey also. The animal was fed with soaked black gram, wheat bran, banana etc. Water added with electrolytes was given during the journey.

Departure from Kolkata - 8.00 pm on 9-3-99

Arrival at Jamshedpur - 11.00 pm on 10-3-99

The Camel was translocated by truck without use of any transportation box but was tied with rope in sitting posture throughout the journey. The floor of the body was heavily padded with paddy straw.

Translocation of Emus 2:2 from Hyderabad during the year 99 by train and truck.

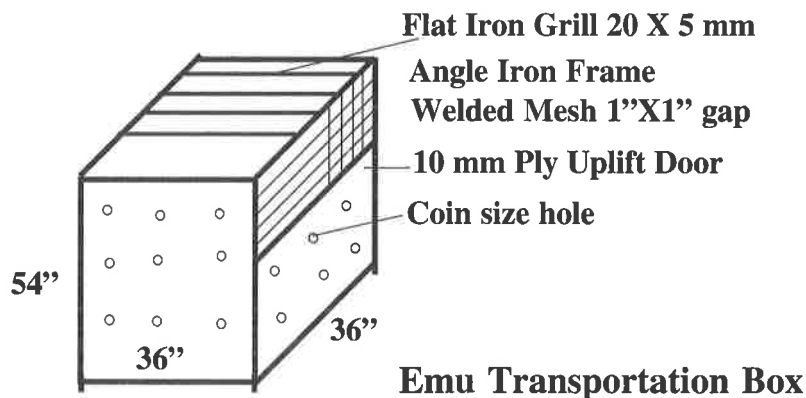
Four no. of 14-16 months old sub-adult Emus were captured manually from enclosure and caged in four cages at 8.00 am on 5-7-99 at Emu farm at Secunderabad and were brought to Railway station by truck. The boxes were kept in the break-van of the train (which was booked in advance). The cages were designed in such a way that all the four cage can be put in a single break van properly and also according to size of doors of van and the size of the bird. One keeper was also allowed to accompany the bird in the same break van so that birds can be looked after properly. Dry ration and drinking water added with multiple electrolytes was provided to the birds during the journey. The door of the van was also kept open so that suffocation can be avoided.

Departure from Secanderabad - 2.00 pm on 5-7-99

Arrival at Khargpur - 5.00 pm on 6-7-99

Departure from Khargpur - 8.00 pm on 6-7-99

Arrival at Jamshedpur - 9.00 am on 7-7-99





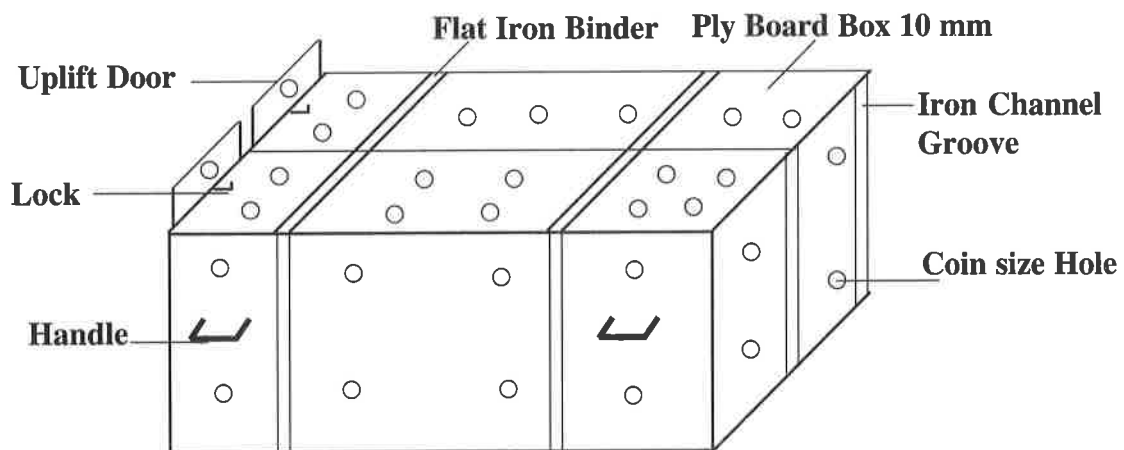
Translocation of Crocodile from Nandan Kanan Biological Park, Bhubaneshwar to Tata Zoo, Jamshedpur

1:3 no. of 1.5 metre size Gharial and 1:1 no. of Caiman crocodiles were translocated from Nandan Kanan Biological Park during Feb.97.

The animals roughly 1.5 metre in length and were captured manually by using gunny bags and caged in transportation box (design as under) at 4.00 pm on 7-2-97. The boxes were loaded on vehicle at 6.00 pm

Departure from Bhubaneshwar - 8.00 pm

Arrival at Jamshedpur - 8.00 am




Crocodile Transportation Box (Size 6'6" X 18" X 18")





Tranquilization of Male Sloth Bear



ABSTRACT

History of cannibalism in captive bears is very rare. One male Sloth Bear in Bear Safari, Bannerghatta Biological Park, Bangalore – 83 had attacked and killed two female sloth bears. The male bear was found to be eating the external genitalia of the female bear. Hence the bear was darted to be kept in holding house. The animal was darted from a distance of 20 feet using Dist- Inject syringe powered by brown charge and propelled by Dist – Inject gun model No 60. The bear was darted at the neck muscles. Xylazine - Ketamine mixture @ 3 mg / kg and @ 8 mg / kg IM respectively was used for immobilization of the sloth bear. Vomition was observed in five minutes post injection of the mixture. After 15 minutes the bear was found to be immobilized, adequate safe for handling. The bear was restrained physically using ropes tied around the shoulders and brought back to the holding house.

Srinivasa Murthy G

Asst. Director

Dilip Kumar Das

Veterinarian

NL Raghava

Asst. Conservator of Forests

Markandaiah KB

Executive Director

Bannerghatta Biological Park
Bannerghatta Post, Bangalore
Karnataka.



Tranquilization of Sloth Bear :

Bear Safari was started in the year 2002-2003 at Bannerghatta Biological Park.

Area - 36.35 acres

Total number of animals in

Bear Safari - 22 nos.

Male - 13

Female - 9

Purpose of Tranquilization

- Psychological disorders
- Cannibalism in the captive adult Sloth Bear

Animal darted from a distance of 20 feet powered with brown charge at neck region.

After dart animal moving towards holding house.

Bear sedated 20 min after darting, note the posture of bear.

Bear brought back from moat to crawl area.

Male Sloth Bear feeding on the carcass of female sloth bear.

Another female sloth bear killed by the same male sloth bear.





**Hand rearing
of
EMU Chicks
at
Arignar
Anna
Zoological
Park,
Vandalur**



Emu, the second biggest bird in existence, is native of Australia. Arignar Anna Zoological Park received 1:1 Emu chicks of three weeks old. The chicks were initially released in a 15 feet x 15 feet sand filled, chain link covered yard. The chicks started to peck and swallow very small pebbles and sand particles. In order to avoid any problem caused by the foreign bodies, very fine sand was filled in the yard and a layer of the same was removed once in a fortnight to avoid faecal contamination. Initially the chicks were fed with germinated green gram, soaked wheat and greens. Broiler starter mash and cooked rice in milk were added gradually. To avoid wastage, feed and water were provided in hanging trays so that the birds can consume with ease. Over feeding was avoided to prevent skeletal deformities. Faecal examination and deworming were done once in a month. After they attained six months of age, the birds were released into the flightless birds enclosure of the zoo and they continue to enjoy the new environment.



K.Senthilkumar

K. Divaki

Veterinary Assistant Surgeons

R. Thirumurugan

Zoo Veterinarian

Pathan Nazrullah Khan

Veterinary Officer

Arignar Anna Zoological Park,
Vandalur, Chennai
Tamilnadu



Experiences on Capture and Translocation of Elephants and Rhinoceros from field



Dr. Kushal Konwar Sarma

Ph.D.

Associate Professor
Surgery & Radiology, CVSc, AAU,
Guwahati, Assam

Why capture them?

- Treatment
- Biological research
- Rescue operation
- Planned breeding
- Control of rogues
- Biotelemetry
- Translocation

Why translocation?

- Population management-
Over population-Carrying capacity
Small population-Inbreeding, unsustainable
- Building back-up populations
- Relocate stray animals

Problems of the operation

- Very expensive
- Expert team is required
- Elaborate preparations are necessary
- Very little margin of error
- Animals come back
- Translocated animals are not accepted by the resident herd.

Past experience

- Asian elephant
Malaysia (1974-1988)
Sri Lanka (1979)
Karnataka (1987)
Tamilnadu (1986)
Assam (1999, 2002)



- Great Indian one-horned rhinoceros
Sale & Woodford (1981)
Nepal- ongoing

ANIMAL SPECIES

- Preparedness
- Individual or herd behaviour
- Physical drive vs Chemical restraint & motorized transportation

Syringe projector

- Projector type and condition- Dist inject long range projector
- Gun powder blanks/ pneumatic
- Reusable metal darts
- Appropriate needle

Drug protocol

- Immobilizing: Etorphine, Carfentanyl, Xylazine, Medetomidine, Romifidine
- Sedative: Xyl., Mede., ACP, Halo
- Reversal: Dipre., Yohim., Atipamezol
- Human antidote: Narcan, Adrenaline, Atropine
- Antistress: Vit.E, Zinc, Selenium
- Myopathy: Sodi-bi-carb inf, Atihist., NSAID
- Analeptics: Doxapram, Nickethemide
- Antishock: Dexta or Betamethasone
- Long acting Ab. Antiseptics & TT

Darting protocol

- Correct approach
- Darting platform

- Darting field
- Darting areas in the body
- Approaching the darted animal

Immobilized animal

- Ensure Immobilization before handling
- Eye ointment, blindfold
- Monitor vital functions and correct
- Collect darts and preserve, dress
- Maintain airways
- Apply physical restraint
- Radio collar, Blood sampling, Measurements

Loading

- Sledge the rhino into the box cage, reverse immobilization
- Push sedative in the elephant, place koonkies and reverse immobilization
- Load into the truck in reverse
- Transport (40km & 30km)

Transportation

- By road- max. 40 km for rhino, 30 km for elephant.
- Pilot car.
- Veterinary car.
- By air.
- By water.
- On foot.

Release

- Appropriate release site
- Post release monitoring





Centre for Wildlife Conservation and disease Surveillance



Main Activities

- Health monitoring and disease surveillance in free and captive wildlife
- Identification and characterization of wild mammalian species
- PG Teaching relating to wildlife health management (NDZWM)

Infrastructure

- Scientific staff: 1 + 6 collaborating scientists
- Technical: 1
- Ministerial: 1
- Supportive staff: 4
- Laboratory: 2 + lab facilities of collaborators
- Deer Park consisting of 33 animals
 - Black buck- 8
 - Chinkara - 1
 - Hog deer - 1
 - Nilgai - 4
 - Spotted Deer-19

CZA Funded Scheme

Title: Development of disease diagnosis and forensic facilities for captive and free range wild animals

Project Leader : Dr M. P. Yadav

P. I. D. Swarup/ I/C CWL

Collaborators: G. R. Singh

A. K. Sharma

A. K. Tiwari

R. C. Patra

A. G. Telang

Dr. D. Swarup
Incharge,
Centre for Wildlife,
Indian Veterinary Research Institute
Bareilly

Objectives

- To investigate and provide diagnosis of diseases in captive and free range wild animals
- To develop molecular biology techniques for identification of wild species



Practical Utility

- To meet the demands for expert diagnostic and forensic facilities to National Zoological Parks and forest department in the country

Activities

- Development of infrastructure and renovation of existing facility to establish diagnostic and forensic laboratory
- Creation of museum of gross pathological specimens and species-wise cataloguing of bones from wild animals
- Attending wild life disease outbreaks and extending the clinical health services
- Necropsy examinations of carcasses and histopathological diagnosis of morbid specimens received
- To generate normal haemato-biochemical parameters in different wild species
- Standardization and use of molecular biology techniques (RAPD-PCR/nucleic acid hybridization) for wildlife species identification
- Identification of bones and other material of wild life for forensic purposes

Activity assigned

- Post mortem & Histopathological examinations (Dr AK Sharma)
- Radiological examination (Dr GR Singh)
- Biochemical/ serological/ toxicological examinations (Dr Ag Telang/ Dr RC Patra, Dr D Swarup)
- Disease investigation and consultancy (Dr D. Swarup, and other specialists)
- Biotechnological methods (Dr AK Tiwari/ Dr Mohini saini)

Services rendered

- Disease diagnosis
- Clinical examination
- Postmortem & histopathological examination
- Radiology
- Forensic aids
- Wildlife Disease management and other advisory services

Main users / linkages

- Zoological parks- Delhi, Lucknow, Kanpur, Nainital
- National parks- Dudhwa, Ranthambor
- Wild life Range & Forests Departments- Wildlife range Kartaniaghat (Baharaich), Forest caretaker Wild Animals Gonda, Social Forestry Deptt. Bareilly, Shahjahanpur and Badaun, ForestDeptt. Haldwani, Haridwar, etc.
- Others- Wildlife Trust of India, Chambal Century Project Agra, Judiciary (Through forests Deptt.)

Post mortem Examinations (1-4-2001-31 to 12-2003)

Animal Species	No of PM	Diagnosis
Tiger	13	Traumatic injury (5) NSD(8)
Leopard	3	Traumatic injury (2) NSD(1)
Deer	4	NSD
Black Buck	3	Traumatic injury (2) NSD(1)
Rhinoceros	1	Traumatic injury
Neelgai	1	NSD
Turtle	1	NSD
Total	26	



Histopathology (350 samples from 77 animals)

Species	No.	Diagnosis
Tiger	6	Hepato-renal deg. (1)
		Parasitic granuloma (1)
Lion	2	Interstitial nephritis (1)
Python	1	Focal necrotic hepatitis(1)
Red Leche	1	Acute serous bronchopneumonia
Black buck	5	Tarsal gland hyperplasia (1)
Squirrel monkey	2	Suppurative myositis (1)
Swamp deer	2	Nephrosis (1)
Lion-tailed monkey	1	Hepatitis (1)

Forensic services

Specimen	Received from
Skin of tiger (4)	CJM Rampur
	CJM Lakhimpur Khiri
Elephant tusks/ teeth (2)	Forests department Pilibhit
Skin of deer (2)	CJM Rampur
	Thana Tanda, Rampur
Tiger bones & skull(4)	Forest Deptt. Pilibhit
	Dudhawa National Park FRO, Nawrangpur
Lion skin and bones (2)	CJM Lakhimpur Khiri
	Dudhawa National Park
Teeth of Wild boar (1)	Dudhawa National Park
Bones of crocodile (1)	Forest deptt, Haridwar
Legs & feather of peacock	Social Forestry deptt. Shahjahanpur

Veterinary Consultancy

- Dudhwa National Park
- Mohinder Mohan Chaudhary Zoological park, Chhatbir
- Pt. GB Pant Zoological Park, Nainital
- Zoological Garden, Lucknow
- Kedarnath Vanya Jeev Prabhag, Gopeshwar

Center for Wildlife Conservation and disease Surveillance in the services of wildlife healthcare

Treatment Consultancy of ailing tiger

- Director Lucknow Zoo requested for vet consultancy to white tiger having bleeding from left canine
- The biopsy indicated squamous cell carcinoma of mild degree
- Radiographic examination taken up by us revealed aggressive and osteolytic nature of lesion suggestive of osteolytic osteosarcoma/ squamous cell carcinoma of sever nature
- Serum biochemistry indicated involvement of kidney and liver
- Treatment (cyclophosphamide 50mg/ m2orally for 3 days /week for 4 week+ Mesna 2ml + prednisolone 10 mg daily for first week prolonged survival

Identification of crocodile bones

- Specimens of skull bones received from Forest officer Haridwar
- On basis of morphologic (18 and 15 teeth upper lower side and largest fifth maxillary tooth) and radiographic examinations, bones were identified as that of muggar (Crcodylus palustris)

Identification of tusk and teeth bones

- Seven specimen received from DFO Pilibhit
- Identified on the basis of morphological (presence of cemented ridge , and texture of dentine similar to molar teeth of an elephant) and radiographic examination (homogenous dense radiographic density suggestive of dense tissue of animal origin)



Identification of Legs of Indian Peacock (*Pavo cristatus*)

- Specimen received from forestry Deptt. Shahjahanpur
- Identified on the basis of morphological (presence of pointed spurs in distal third of shank, long tarso-metatarsus and short blunt and strong claws), and radiographic examination (confirming presence of leg bones).

Future activities /linkages

- Continuing consultancy services indicated above
- Establishing normal hematobiochemical

profile of spotted deer and black buck for use as reference value

- Developing biotechnological methods to characterize meat/ tissue samples of Deer vs cattle and buffaloes and other wild animals vs related domestic species
- Purchase of equipments

Funding

- More funds are required to continue the project for one more year
- CZA is requested to consider additional funds of Rs 4 lakh to continue the post of 2 RA and purchase of essential consumables



Enrichment of Technical Liaisonship between Zoos & Veterinary Research Institution



Dr.M.G. Jayathangaraj

Ph.D., D.WL.Mgt.,
Associate Professor &
Head, Dept.of Wildlife Science,
Madras Veterinary College
Chennai-7

TEAM APPROACH FOR MOST OF THE PROBLEMS- ADAPTED AS A BASIC STEP

Clinical signs Wild animals! (often unpredictable)

Biology – a speciality !21

Immobilisation – a problem

Treatment –again problem

Factors involved:

Zoo + vet.research inst.

FACILITATING OPPORTUNITIES FOR LIAISONSHIP

TRAININGS

PROJECTS

CURRICULUM WORKS IN VCI SYLLABUS

CLINICAL BACKGROUND

INTERACTIONS WITH ZOO VETERINARIANS

& FOREST OFFICIALS INCLUDING ANIMAL KEEPERS

PROBLEM IDENTIFICATION IN ZOO SET UP

- AN OPEN TYPE OF INTERACTIONS
- REVEALING OF PROBLEMS PRECISELY AND FRANKLY
- UNDERSTANDING OF MANAGEMENT ISSUES
- INTERACTIONS ON VETERINARY INFORMATIONS FOREST OFFICIALS FRANKLY
- NET APPLICATIONS (BASED ON UTILITIES!)

SPECIFIC CHANNELS FOR ENRICHMENT OF LIAISONSHIP

PROJECT :

- STRENGTHENING OF MADRAS VETERINARY COLLEGE AS NODAL CENTRE OF WILDLIFE HEALTH AND DISEASE DIAGNOSIS
- FIELD LEVEL COOPERATION & ASSISTANCE
 - ZOO DIRECTORS
 - VICE CHANCELLOR OF TANUVAS



OBJECTIVES OF THE PROJECT

- Clinico-pathological and physiological analysis
- Toxicology, metabolic and nutritional analysis
- Microbiological and serological analysis and preventive care
- Clinical diagnosis by non-invasive diagnostic equipments and methods

- TOXACARA SP. WORMS IN FELIDS
- APONOMMA SP. TICKS IN COBRA AT ZOOLOGICAL PARK
- METABOLIC BONE DISORDER OF MUGGER
- STAR TORTOISE AT AMRIDI ZOO
- AUTOPSY OF CHIMPANZEE AT ZOOLOGICAL PARK
- LESION DUE TO FRACTURE IN CHIMPANZEE
- STORNGYLOIDES STERCORALIS IN B. MACAQUE
- BALANTIDIUM COLI IN NON-HUMAN PRIMATE
- ANCYLOSTOME EGG IN CIVET CAT
- LILOPTENA CERVI FLY IN CHITAL
- FEED ANALYSIS IN AAZP
- INTERACTIONS WITH ZOO VETS AT PARK

TECHNICAL DISCUSSIONS WITH ZOO VETS AND INTERNATIONAL EXPERT- DISSEMINATION MEASURE

- REGIONAL CONTRIBUTION-MYSORE
- POST MORTEM OF HIPPOPOTAMUS OF PARK
- HYDATID CYST – LIVER - LION
- SUPPURATIVE PNEUMONIA – LUNG - BLACKBUCK

- EOSINOPHIL IN MUGGER
- GADGET FOR ZOO VETERINARIANS
- REVEALING OF ANATOMICAL FEATURES AT ZOO

ENHANCING RESEARCH ACTIVITIES FOR BETTERMENT OF WILD ANIMAL HEALTH CARE

- ENHANCING RESEARCH ACTIVITIES FOR BETTERMENT OF WILD ANIMAL HEALTH CARE
- AMPLIFIED STETHOSCOPE
- PRIMATE CAMP AT ZOOLOGICAL PARK
- PULSE OXIMETRY IN LTM
- PULSE OXIMETRY IN BONNET MACAQUE

Regional contributions will be Strengthened
CONSTRAINTS

Travel grant

Communications

CONCLUSION IN ONE WORD

- BOTH ZOOS & VETERINARY
- RESEARCH INSTITUTIONS
- HAVE BENEFITS !!





Resource Persons who attended the conference on 3rd Feb. 04

1. Dr. B. M. Arora

President,
Association of Indian Zoo and Wildlife
Veterinarians,
M-83 BDA. Colony,
Tibri Nath Mandir, Bareilly.
U.P. -243122

2. Dr. D. Swarup

Incharge,
Centre for Wildlife,
Indian Veterinary Research Institute
Bareilly.

3. Dr. K.K. Sharma

Prof.
College of Veterinary Science
Guwahati.
Assam

4. Dr. L.N. Acharjyo

Retd. Zoo Veterinarian,
Nandankanan Biological Park,
Bhubaneswar.
Orissa

5. Dr. M.G. Jayathangaraj

Principal Investigator
Dept. of Wildlife Science,
Madras Veterinary College,
Chennai.

6. Dr. N. Sahoo

Officer Incharge
Wildlife Health Center,
Orissa Veterinary College,
Bhubaneswar.
Orissa

7. Dr. R.G. Jani

Prof. & Incharge,
Center for Wildlife Health,
Veterinary College,
Anand, Gujrat.



List of Veterinarians who attended the conference on 3rd Feb. 04

1. **Dr. Avijit Biswas**
Veterinary Officer,
Alipore Zoo, Kolkata.
West Bengal.
2. **Dr. Anil Sharma**
Veterinary Officer,
Bhopal Zoo,
Bhopal
3. **Dr.B.S. Bhadashiya**
Veterinary Officer,
Geer Foundation
Indroda Nature Park PO. Sector -7
Gandhi Nagar, Gujrat.
4. **Dr. C.N. Bhua**
Vet. Officer,
Sakkarbaug Zoo,
Junagadh,
Gujarat.
5. **Dr.C.S. Jayakumar**
Veterinary Officer,
Thiruvanthapuram Zoo,
Zoological Gardens,
Thiruvanthapuram City, Kerala.-695033
6. **Dr.Devendra Porwal**
Veterinary Officer,
Kamla Nehru Prani Sangharahalya Zoo,
Indore Zoo,
Indore , Navlakha,
M.P-452001.
7. **Dr. Denesh Kumar Pradip**
Veterinary Officer,
Bhagwn Birsa Biological Park,
Doranda , P.B.No-41
Ranchi
Jharkhand-831001
8. **Dr. G. Srinivasamurthy**
Veterinary Officer,
Bannerghatta Biological Park,
Bangalore.
Karnataka-560083
9. **Dr. J.B. Goswami**
Veterinary Officer,
Ahmedabad Zoo
Gujrat.
10. **Dr.Jikom Panor**
Veterinary Officer,
Biological Park,
Itanagar Wildlife Sanchuary Division,
Naharlagur,
Arunachal Pradesh-791110
11. **Dr. K.D. Batwe**
Veterinary Officer,
Sanjay Gandhi National Park,
Borivali, Mumbai
12. **Dr. Kallappa**
Veterinary Officer,
Lion & Tiger Safari,
Thyavarekoppa, Wlidlife Division
Shimoga.
Karnataka-577201
13. **Dr.M. Palit,**
Veterinary Officer,
Tata Steel,Zoological Park
Jubilee Park,
Jamshedpur.(Jharkhand)-831001
14. **Dr. M. G. Maradia,**
Veterinary Officer,
Rajkot Zoo,
Rajkot, Gujrat.



- 15. Dr. Malay Maity**
Veterinary Officer,
PNHZ Park, Darjeeling.
West Bengal
- 16. Dr. M.S. Chaudhary**
Vet. Officer
Jaipur Zoo, Ramnivas Bagh,
Jaipur , Rajsthan
- 17. Dr. N. K. Jain**
Vet. Officer
Maitribaag Zoo, Bhilai Steel Plant
Bhilai, Orissa
- 18. Dr. Rajeev Tripathi**
Veterinary Officer,
Kanpur Zoological Park,
Kanpur. U.P.
- 19. Dr. R.K. Sahoo**
Veterinary Officer,
Indira Gandhi Park
Zoo and Deer Park
Town service Department
Rourkela Steel Plant
Sector -4 . Rourkela
Orissa-769002
- 20. Dr.R.K. Samantarai**
Veterinary Officer,
Nandan Kanha Zoo,
Bhunashuar .
Orissa
- 21. Dr. Srinivas**
Veterinary Asst. Surgeon,
Indira Gandhi Zoological Park,
Visakhapatnam.530040
- 22. Dr. S.K.Mittal**
Veterinary Officer,
Gandhi Zoological Park,
Gwalior.M.P.
- 23. Dr. Sushil Sood**
Veterinary Officer,
Himalayan Nature Park (Kufri)
Himachal Pradesh Forest Department
Wildlife Division, Shimla.
Himachal Pradesh-171002
- 24. Dr. Shashi Kant Ajay**
Veterinary Officer,
Sanjay Gandhi Biological Park
Patna, (Bihar).
- 25. Dr. S.C. Valandikar**
Veterinary Officer,
Sri Chamarajendra Zoological Garden,
Indira Nagar
Mysore.
Karnataka
- 26. Dr.D.V. Shukla,**
Veterinary Officer,
Sundervan Nature Discovery Centre
Jodhpur Tekra, SM. Road
Ahmedabad.-3380015
Gujrat
- 27. Dr.M.S. Karavle,**
Asst. Supdt. (Vet.)
Brihan Mumbai MahanagarPalika,
Veermata Jijabai Bhosle Udyan-Zoo,
Dr. Ambedkar Road,
Byculla Mumbai-400027.
- 28. Dr. L. K. Sanwal**
Vet. Officer,
G.B.Pant High Altitude Zoo,
Nainital, Uttranchal .
- 29. Shri Bipul Chakrabarty**
CZA(Ministry of Environment & Forest)
Bikaner House, Annexe-6
Sahjahan Road,
New Delhi.



- 30. Shri Brij Kishor Gupta, (Scientist)**
CZA(Ministry of Environment & Forest)
Bikaner House, Annexe-6
Sahjahan Road,
New Delhi
- 31. Dr. C.B.Patel,**
Vet. Officer,
Sayaji Baug Zoo, Vadodara
- 32. Dr. N.S. Manoharan,**
Zoo Director,
V.O.C. Park Zoo,
Coimbatore.
- 33. Dr. Santosh Kr. Bhowmik,**
Ass. Director,
Vet.of Sepahijala Zoo
Tripura.
- 34. Dr. Nirmaljit Singh**
Vet. Officer,
M.C. Zoological Park,
Chhatbir Punjab,
Chandigarh.
- 35. Shri Vanlalhruaia Pachuau**
Wildlife Division,
Aizawl, Mizoram.
- 36. Dr. George Verghese**
Senior Vet. Officer
Dept of environment & Forest, Port Blair ,
Andamans
- 37. Dr. B.K. Gogoi**
Pathologist,
Assam State Zoo,
Guwahati
- 38. Dr. Pathan Nazrullah Khan**
Arignar Anna Zoological Park,
Vandalur, Chennai,
Tamilnadu
- 39. Dr. Dr. Ranaware R.V.**
Maharashtra
- 40. Dr. Utkarsh Shukla**
Zoo Vet. & Dy Director
Lucknow Zoological Gardens,
Lucknow, U.P.
- 41. Dr. Ashok Kashyap**
Asstt. Vet.
Lucknow Zoological Gardens,
Lucknow, U.P.



LIST OF BIRDS REPORTED FROM LUCKNOW ZOO

Sl. Name	(हिन्दी नाम)	Scientific name	Systematic No.
Family PODICIPEDIDAE			
1. LITTLE GREBE	(डुबडुबी)	<i>Tachybaptus ruficollis</i>	(5)
Family PHALACROCORACIDAE			
2. LITTLE CORMORANT	(छोटा जलकौवा)	<i>Phalacrocorax niger</i>	(28)
3. DARTER	(पनडुब्बी)	<i>Anhinga melanogaster</i>	(29)
Family ARDEIDAE			
4. GREY HERON	(सिलेटी अंजन)	<i>Ardea cinerea</i>	(36)
5. INDIAN POND HERON	(चामा अंजन)	<i>Ardeola grayii</i>	(42)
6. CATTLE EGRET	(बादामी बगुला)	<i>Bubulcus ibis</i>	(44)
7. LITTLE EGRET	(छोटा बगुला)	<i>Egretta garzetta</i>	(49)
8. BLACK-CROWNED NIGHT HERON	(रात्रि अंजन)	<i>Nycticorax nycticorax</i>	(52)
Family CICONIIDAE			
9. PAINTED STORK	(रंगीन जांघिल)	<i>Mycteria leucocephala</i>	(60)
Family ACCIPITRIDAE			
10. BLACK KITE	(काली चील)	<i>Milvus migrans govinda</i>	(133)
11. SHIKRA	(शिकरा)	<i>Accipiter triviragatus</i>	(144)
12. NORTHERN SPARROW HAWK	(बाशा)	<i>Accipiter nisus</i>	(148)
13. EGYPTIAN VULTURE	(कोल गिद्ध)	<i>Neophron percnopterus</i>	(186)
Family PHASIANIDAE			
14. INDIAN PEAFOWL	(मोर)	<i>Pavo cristatus</i>	(311)
Family RALLIDAE			
15. WHITE-BREASTED WATERHEN	(दौक)	<i>Amaurornis phoenicurus</i>	(343)
Family CHARADRIIDAE			
16. RED-WATTLED LAPWING	(टिटहरी)	<i>Canellus indicus</i>	(366)
Family RECURVIROSTRIDAE			
17. BLACK-WINGED STILT	(टिनघुर)	<i>Himantopus himantopus</i>	(430)
Family COLUMBIDAE			
18. YELLOW-FOOTED GREEN PIGEON	(हरियल)	<i>Treron phoenicoptera</i>	(503)
19. ROCK PIGEON	(नीला कबूतर)	<i>Columba livia</i>	(520)
20. EURASIAN COLLARED DOVE	(झोर फाख्ता)	<i>Streptopelia decaocto</i>	(534)
21. SPOTTED DOVE	(चित्तीदार फाख्ता)	<i>Streptopelia chinensis</i>	(537)
22. LAUGHING DOVE	(हंसी फाख्ता)	<i>Streptopelia senegalensis</i>	(541)
Family PSITTACIDAE			
23. ALEXANDRINE PARAKEET	(हीरामन तोता)	<i>Psittacula eupatria</i>	(546)
24. ROSE-RINGED PARAKEET	(लहबर तोता)	<i>Psittacula krameri</i>	(549)
25. PLUM-HEADED PARAKEET	(टुंझ्यां तोता)	<i>Psittaculcyanocephala</i>	(557)
Family CUCULIDAE			
26. PIED CUCKOO	(कुहुक)	<i>Clamator jacobinus</i>	(570)
27. ASIAN KOEL	(कोयल)	<i>Eudynamis scolopacea</i>	(590)
28. GREATER COUCAL	(बड़ा महोक)	<i>Centropus sinensis</i>	(600)



Family STRIGIDAE

29. JUNGLE OWLET (जंगली चोगद) *Glaucidium radiatum* (636)
30. SPOTTED OWLET (धब्बेदार चोगद) *Athene brama* (650)

Family APODIDAE

31. HOUSE SWIFT (बबीला अवाबील) *Apus affinis* (703)

Family ALCEDINIDAE

32. PIED KINGFISHER (चित्तीदार किलकिला) *Ceryle rudis* (719)
33. WHITE-THROATED KINGFISHER (सफेदगर्दन किलकिला) *Halcyon smyrnensis* (736)

Family MEROPIDAE

34. GREEN BEE-EATER (हरा पतरिगा) *Merops orientalis* (750)

Family CORACIIDAE

35. INDIAN ROLLER (नीलकंठ) *Coracias benghalensis* (755)

Family UPUPIDAE

36. COMMON HOPPOE (हुदहुद) *Upupa epops* (763)

Family BUCEROTIDAE

37. INDIAN GREY HORNBILL (सिलेटी धनेश) *Tockus birostris* (767)

Family CAPITONIDAE

38. BROWN-HEADED BARBET (भूरेशिर का खोटुर) *Megalaima zeylanica* (780)
39. COPPERSMITH BARBET (सतरंगा खोटुर) *Megalaima haemacephala* (792)

Family PICIDAE

40. BLACK-RUMPED WOODPECKER (कालीपूँछ का कठफोड़ा) *Dinopium benghalense* (819)
41. BROWN-CAPPED PIGMY WOODPECKER (भूरासर कठफोड़ा) *Dendrocopos nanus* (851)

Family ALAUDIDAE

42. SMALL SKYLARK (छोटा अगिया) *Alauda gulgula* (905)

Family LANIIDAE

43. LONG-TAILED SHRIKE (लंबीपूँछ लटोरा) *Lanius schach* (947)

Family ORIOLIDAE

44. EURASIAN ORIOLE (सुनहरा पीलक) *Oriolus oriolus* (952)

Family DICRURIDAE

45. BLACK DRONGO (काला भुजंगा) *Dicrurus adsimilis* (962)

Family STURNIDAE

46. CHESTNUT-TAILED STARLING (भूरीपूँछ स्टारलिंग) *Sturnus malabaricus* (987)
47. BRAHMINY STARLING (ब्रहमीनी स्टारलिंग) *Sturnus pagodarum* (994)
48. ASIAN PIED STARLING (पाइड स्टारलिंग) *Sturnus contra* (1002)
49. INDIAN MYNA (देसी मैना) *Acridotheres tristis* (1006)
50. BANK MYNA (बैंक मैना) *Acridotheres ginginianus* (1008)
51. JUNGLE MYNA (जंगली मैना) *Acridotheres fuscus* (1009)

Family CORVIDAE

52. RUFOUS TREEPIE (लाल कोकीया) *Dendrocitta vagabunda* (1030a)
53. HOUSE CROW (देसी कौवा) *Corvus splendens* (1049)
54. LARGE-BILLED CROW (जंगली कौवा) *Corvus macrorhynchos* (1054)

Family PYCNONOTIDAE

55. RED-WHISKERED BULBUL (लालगाल बुलबुल) *Pycnonotus jocosus* (1123)



56. RED-VENTED BULBUL	(लालपूँछ बुलबुल)	<i>Pycnonotus cafer</i>	(1131)
Family MUSCICAPIDAE, Sub family TIMALINAE			
57. COMMON BABBLER	(सामान्य पनदोआ)	<i>Turdoides caudatus</i>	(1254)
Sub family MUSCICAPINAE			
58. ASIAN PARADISE FLYCATCHER	(स्वर्ग तीली)	<i>Terpsiphone paradisi</i>	(1460)
Sub family SYLVIINAE			
59. ASHY PRINIA	(सिलेटी फुटकी)	<i>Prinia socialis</i>	(1515)
60. TAILOR BIRD	(दरजी फुटकी)	<i>Orthotomus sutorius</i>	(1535)
Sub family TURDINAE			
61. ORIENTAL MAGPIE ROBIN	(धैयर)	<i>Copsychus saularis</i>	(1661)
62. BROWN ROCK CHAT	(दौमा)	<i>Cercomela fusca</i>	(1692)
63. INDIAN ROBIN	(कलचुरी)	<i>Saxicoloides fulicata</i>	(1717)
Family MOTACILLIDAE			
64. WHITE WAGTAIL	(सफेद धोबन)	<i>Motacilla alba</i>	(1885)
65. WHITE-BROWED WAGTAIL	(सफेदभौ धोबन)	<i>Motacilla maderaspatensis</i>	(1891)
Family NECTARINIIDAE			
66. PURPLE SUNBIRD	(काला शकरखोरा)	<i>Nectarinia asiatica</i>	(1917)
Family ZOSTEROPIDAE			
67. ORIENTAL WHITE-EYE	(बबूना)	<i>Zosterops palpebrosa</i>	(1933)
Family PLOCEIDAE, Sub family PASSERINAE			
68. HOUSE SPARROW	(गौरैया)	<i>Passer domesticus</i>	(1938)
Sub family PLOCEINAE			
69. BAYA WEAVER	(बया)	<i>Ploceus philippinus</i>	(1957)
Sub family ESTRILDINAE			
70. RED AVADAVAT	(लाल मुनिया)	<i>Amandava amandava</i>	(1964)
71. GREEN AVADAVAT	(हरी मुनिया)	<i>Amandava formosa</i>	(1965)
72. SCALY-BREASTED MUNIA	(चित्तीदार मुनिया)	<i>Lonchura punctulata</i>	(1974)
73. BLACK-HEADED MUNIA	(कालासिर मुनिया)	<i>Lonchura malacca</i>	(1976)

Systematic nos. used in this list are based on book - "Birds of Indian Subcontinent"
by Dr. Salim Ali and S. Dillon Ripley.

Eva Sharma

Director
Lucknow Zoological Gardens
Lucknow

Weighing meat for carnivores



Washing of vegetables



Preparing food for animals



Treatment of animals



Pheasants eggs - ready for hatching



Zebra baby - Hand rearing

