


TECHNIQUES & PROCEDURE FOR POST-MORTEM OF ELEPHANTS



TECHNIQUES & PROCEDURE FOR POST-MORTEM OF ELEPHANTS

**A Handbook for
Veterinarians, Biologists & Elephant Managers**

Authors

Dr. Jacob V. Cheeran

Former chairman,
Elephant Study Centre,
Kerala Agricultural University

&

Dr. N. Diwakaran Nair

Associate Professor
Centre of Excellence in Pathology,
College of Veterinary and Animal Sciences,
Kerala Agricultural University

Published by

Project Elephant

and

Central Zoo Authority

Ministry of Environment and Forests
New Delhi

© Project Elephant,
Ministry of Environment & Forests
Government of India
First Edition 2003

All rights reserved. No part of the book may be reproduced in any form or by any means without the written permission of Director, Project Elephant, Ministry of Environment & Forests, Government of India, New Delhi.

Photo credits: 1 to 5: Dr. N. Vijayan; 6 & 7: Dr. K.C. Panicker.

This handbook is the joint publication of Project Elephant and Central Zoo Authority, Ministry of Environment & Forests, Government of India, New Delhi.

CONTENTS

Preface

Introduction

- | | |
|---|-------------|
| 1. Anatomical features of elephants | Page: 1-3 |
| 2. Post-mortem techniques and procedure | Page: 5-15 |
| 3. Collection, preservation and despatch of material for laboratory examination | Page: 17-27 |
| 4. Collection and preservation of material for toxicological examination | Page: 29-31 |

Appendix

- | | |
|--|-------------|
| 1. Check list for fixed tissues | Page: 33-34 |
| 2. Specimen for toxicological examinations | Page: 35-36 |
| 3. Estimating the age of Elephants | Page: 37 |
| 4. Metal detector – specifications | Page: 38 |
| 5. Supplementary reading | Page: 39-40 |

Plates (Photos)

- | |
|--|
| 1. Transportation to Post-mortem site. |
| 2. Liver – Sub capsular haemorrhage. |
| 3. Spleen – localised haemorrhage. |
| 4. Duodenum – ulcer in the mucosa extending to the serosa. |
| 5. Petichael haemorrhage – serosa, intestine. |
| 6. Colon wall – ruptured due to impaction. |
| 7. Tuberculosis abscess in the lung. |
-

PREFACE

Post-mortem of elephants is an unpleasant yet inevitable situation that all elephant-managers have to face every now and then. Asian elephant is an endangered species needing protection throughout its range. It needs protection against poaching as well as diseases. Post-mortem gives clues about the mode of death and provides valuable evidence needed for initiating legal action against the accused. It is also an important tool for health monitoring of elephants — both wild and captive. A proper diagnosis of the cause of death provides the elephant-managers with information required for planning preventive and remedial measures to deal with similar situations in future.

However, the fact remains that in a large number of cases of elephant mortality in the country, post-mortem reports are either inconclusive or defective. The reason can be lack of adequate knowledge among the veterinarians and elephant-managers about the necropsy techniques relevant to the animal. There is a great scarcity of experienced and skilled elephant-Vets in the country. The Project Elephant — an ambitious programme of the Government of India launched in 1992 for conservation of elephants, has taken certain initiatives for redressing the situation and this handbook is the outcome of one such initiative. This handbook provides valuable information and tips to the veterinarians and field officers on post-mortem techniques appropriate to elephants. Dr. J.V. Cheeran, a well-known veterinary expert and a member of the Steering Committee of Project Elephant, and his colleague, Dr. N.D. Nair, were entrusted with the responsibility of preparing this handbook. All available literature was consulted during the preparation of this handbook. Comments on the draft were invited from other leading veterinary experts in the country. Editing and revision of the manuscript was undertaken by Shri S.S. Bist, IGF & Director (Project Elephant). I congratulate the authors and the editor for their hard work. However, the utility of a handbook of this nature will ultimately be judged by its acceptance and application by the veterinarians and elephant-managers in the field. We will look forward to their valuable feedback and criticism for further improvement of this handbook.

New Delhi; July 14, 2003

VINOD RISHI
Addl. Director General of Forests
(WILDLIFE)
Government of India

INTRODUCTION

The utility of domesticated elephants to man as a source of animal energy, tourism promotion activity and for conventional festivities is on the increase. But, along with that, the management of this species has become all the more important since they are susceptible to various injuries and diseases. The mortality of elephants is also brought to the notice of the concerned departments more often than in olden days. The professionals, including the veterinarians should be equipped both with facilities for post-mortem and up to date information about this species. In India, data on prevalence of diseases in wild animals is almost non-existent and properly conducted post-mortem can help in bridging the gap.

A systematic procedure and an unhurried technique must be followed to arrive at a correct diagnosis. For a thorough systematic necropsy examination, skill of the vets, the method and the implements to be used should be standardised. No systematic procedure has so far been prescribed for elephants suitable to Indian conditions. Elephants being larger in size need special attention and expertise in dissecting and it is better to follow a pattern, which suits to all situations. Hence, it is necessary to systematise the post-mortem procedure for improving the efficacy of learning process and improve our knowledge regarding elephants.

Post-mortem of elephant is a laborious task. On many occasions the carcass would have decomposed and may not yield any useful information on post-mortem. But whatever possible should still be done. Poaching is another important factor in elephant post-mortem and we recommend the use of a metal detector in addition to eliciting information and conducting local investigation.

This handbook is intended for the veterinarians, wildlife biologists and forest officers working in this field. Some of the pathological changes are described in purely technical terms. This is to avoid the ambiguity in interpreting the findings.

Our special thanks to Ms. Sabitha and Mr. Sreejith T. Chandran who helped to document the majority of the work related to this handbook. We also thank Mr. S.S. Bist, IGF & Director of Project Elephant, who has thoroughly revised and edited the manuscript to enhance its utility for the users.

-Dr. Jacob V. Cheeran
-Dr. N. Diwakaran Nair

Chapter-1

ANATOMICAL FEATURES OF ELEPHANTS

Understanding the anatomy of an elephant is the *sine qua non* for successful post-mortem of the animal. The following notes are meant to provide the field veterinarians with a basic understanding of the special anatomical peculiarities of elephants.

1. Digestive system

- The proboscis, though a respiratory organ, acts as a prehensile organ to grasp the food and conveys it to the mouth for mastication.
- The lips are two musculo-membranous folds which surround the orifice of the mouth. The upper lip merges with the lower face of the proboscis. The lower lip is elongated with a pointed tip.
- The upper jaw has two incisors or tusks, one in each premaxilla. The tusks of the male grow to an enormous size in the adult Asian elephants. They are relatively much smaller in the female. There are male elephants which do not have tusks and are called *Makhnas*. Both cows and *Makhnas* possess tushes instead of tusks.
- The sub-lingual salivary gland and the sub-maxillary glands are present. The tonsils are absent.
- The pharynx is a funnel shaped musculo-membranous sac common to both digestive and respiratory system. The soft palate divides the cavity into a dorsal large nasopharynx and a ventral small oesopharynx. The oesophagus communicates in front with the oral cavity and forms a deep diverticulum or receptacle (glosso-epiglottic space) behind the root of the tongue.
- Oesophagus, a thick walled musculo-membranous tube, is compressed dorsoventrally.
- The peritoneum, lining the abdominal cavity, is very thick and is reflected to cover the viscera. The greater omentum, which is one such reflection, is thin, lace like and devoid of fat. It is very extensive, attached to the greater curvature of the stomach and the origin of the duodenum.

- Stomach is a simple elongated musculo-membranous sac placed vertically behind the left part of the diaphragm and the liver.
- Small intestine is a mucous membrane forming longitudinal and transverse folds in honeycomb patterns.
- Diaphragmatic face of liver is strongly convex and the visceral face is deeply concave. The deep umbilical fissure divides the organ into a larger right and a smaller left lobe. The right lobe is extensive. The gall bladder is absent.
- Pancreas is dark brown, lobulated and situated in the mesoduodenum.

2. Respiratory system

- Proboscis is highly mobile, tactile and prehensile organ. It is made up of two nasal tubes separated by the septum nasi. The anterior margin of the tip of the proboscis has the “prehensile finger” which is highly tactile.
- The parietal pleura are very thick and adherent to the visceral pleura completely obliterating the pleural cavity. The parietal pleura are closely attached to the thoracic wall and are easily separable from the thoracic wall due to the abundance of the endothoracic fascia.
- The left lung is smaller and extends from the 3rd rib to the 16th rib. Deep fissures mark the apical, cardiac and diaphragmatic lobes. The right lung is larger and extends from the 2nd rib to the 16th rib. Mediastinal lobe is attached to it.

3. Cardiovascular system

- Heart is situated in the middle mediastinum extending from the 1st to the 5th rib with the apex resting on the 4th interchondral space. It is large, ovoid and longer on the left side.
- The apex of the heart in majority of the cases is bifid, *incisura cordis* separating the two apices of the ventricles.

4. Urinary system

- The kidneys are multipyramidal, lobulated and covered by a dense layer of connective tissue and fat. The left kidney is placed ventral to the vertebral ends of the last four ribs. The dorsal face is convex while the ventral face is flat. The right kidney is larger than the left. It is situated under the vertebral ends of the last three ribs.
- Urinary bladder is small and pyriform lying at the pelvic inlet.

5. Genital system

- Ovaries are oval and flat on the sides, situated in the abdomen, ventral to the iliac crest and posterior pole of the kidneys.
- Testes are situated on each side medial to the caudal pole of the kidneys.
- There are two pectoral mammary glands. Each gland has a small conical teat. It is placed between the front legs with multiple openings.

6. Haemopoietic system

- There are only a few lymph nodes in the mesentery.
- Hemal nodes are dark brown in colour, intercalated in the course of the blood vessels. These are more in number as compared to the lymph nodes.
- Spleen is in the shape of a dark and elongated organ, wide in the middle and pointed at both the ends. It is vertical in position and is related to the left abdominal wall. The caudal border has a number of notches.

7. Brain

- Elephant has a brain only four times the size of that of man. It has a large cerebral cortex.

8. Skeletal system

Vertebrae — C 7, T 19-20, L 3-5

S 3-5, Cd 24-34

Ribs — 38 in 19 pairs (Sternal-6, Asternal-9, Floating ribs-4)



Transportation to Post mortem site

Chapter-2

POST-MORTEM TECHNIQUES AND PROCEDURE

A systematic necropsy examination is an important tool that is indispensable to an intelligent and scientific understanding of the disease process. Necropsy examination should be viewed as an important learning opportunity and is best accomplished by facts accurately recorded and objectively interpreted. It should be carried out by a skilled person to obtain the pertinent information. It is essential to pay due attention to understand the methodology and interpretation of necropsy findings. History, symptoms, necropsy findings and results of laboratory tests are very essential for a precise diagnosis.

Some points to remember

Whenever possible conduct the entire post-mortem in good daylight. Post-mortem findings are immediately noted down or, preferably, dictated during the progress of the operation.

A proper authority should be obtained for a necropsy before undertaking it. Elephant is an animal included in Schedule-I of the Wildlife (Protection) Act, 1972. Therefore, necropsy must be carried out either under the supervision or with the consent of the appropriate forest authorities. State laws may also place certain restrictions on the necropsy of an animal dead of communicable disease.

Anthrax is often reported in elephants. Hence collect blood smear and examine it before the carcass is opened. Also look for any chances of malicious poisoning, particularly in areas where crop depredation is prevalent.

It is very important to observe strict hygienic practices while performing a necropsy, so that the persons conducting or helping in post-mortem do not endanger their health.

Superficial post-mortem changes

The necropsy should be performed as soon after death as possible, since post-mortem decomposition sets in rapidly, especially in hot weather. A

cadaver may take any thing from one hour to twenty-four hours to cool down. This depends on ambient temperature and exposure to rain and wind. At times a post-mortem rise in temperature is noticed for several hours. This is due to the continuation of tissue metabolism after death and also failure of heat dissipation mechanism, like circulation and respiration. Sometimes, a veterinarian is expected to give his opinion regarding the time of death. This may be possible to determine it approximately by noting post-mortem changes such as cadaveric lividity, rigor mortis and other signs of putrefaction as mentioned below:

1. Cadaveric lividity (hypostatic congestion):

Cadaveric lividity is common in a large animal like elephant. These are irregular livid patches noticed in the subcutis of the side upon which the animal has been lying. These livid patches may be differentiated from a haemorrhage by the fact that the surface of a haemorrhage is elevated on account of the blood escaping through walls of the veins into the adjacent connective tissue, whereas in the livid spots such elevation does not take place since blood remains within the veins.

2. Rigor mortis:

This may set in immediately after death. It may be delayed by 4 to 24 hours or even longer. In weak and emaciated animals rigor sets in earlier and is less pronounced than in healthy and well nourished. Usually it appears within 1-4 hours after death and lasts for 16-18 hours and, at times, even up to 48 hours depending upon the ambient temperature. Rarely it may pass off within 3 hours.

3. Decomposition:

Usually decomposition begins from 6 to 36 hours and again depending upon the time of death, atmospheric moisture and temperature. When advanced post-mortem changes take place, the muscles get softened, become pale red and watery, resembling slightly cooked meat.

Post-mortem instruments

The Instruments most commonly required are:

1. Large knives
2. Axe (small and big)
3. Handsaws

4. Chain saw and hack-saw
5. Bone cutter
6. Crow-bar
7. Hammer and chisels
8. Scalpel handles
9. Scalpel blades
10. Surgical scissors
11. Forceps
12. Chisel
13. Iron spatula
14. Ropes
15. Magnifying glass
16. Torches (Flash light)
17. Emergency lamps/Generator
18. Camera
19. Vehicle fitted with light focussing facilities.
20. Metal detector (to search bullets)

Other accessories required

1. 10% neutral buffered formalin.
2. Sterile instruments for culture collection
3. Culture swabs
4. Glass slides
5. Containers for sample collection
6. Labels and waterproof marking pens
7. Tape measure
8. Gloves

Post-mortem procedure

1. History of management

- Collect information on clinical disease and treatment and previous ailments in case of captive elephants.
- Information should be collected on the circumstances under which the disease was contacted by the animal, the symptoms shown and the

diagnosis that may have been made. Particulars should also be obtained for the treatment received by the animal and the mode of its death.

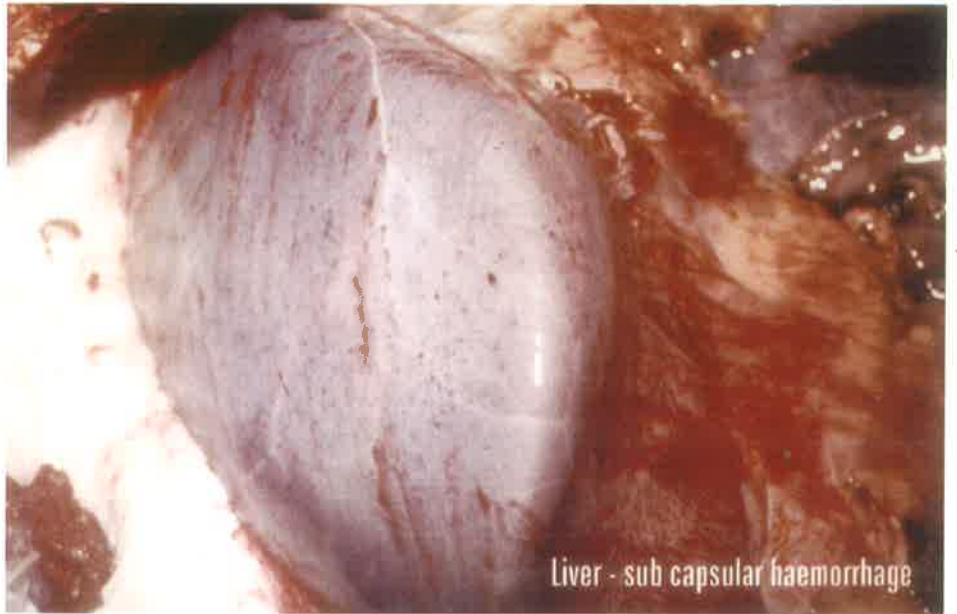
2. External Examination

- Identify sex. Inspect the mammary glands in the female; the prepuce, penis and testicles in the male; and the navel in a newly born animal. A note should also be made whether an animal is pregnant, lactating or dry.
- Note the position of the carcass.
- Note the condition of the animal. Prominent ribs, deep lumbar, buccal depression, distinct temporal fossa, and very loose skin all suggest poor condition.
- Look for any evidence of dislocations and fractures, and also signs of putrefaction.
- Examine the skin for parasitic infestations, lesions of pox, oedematous swellings, emphysematous crepitation, injuries, burns, and the visible mucous membranes for pallor, congestion, cyanosis and inflammatory conditions.
- Examine the skin for swellings, wounds, eruptions, ectoparasites (louse and ticks), cutaneous filariasis, and warts.
- Examine for signs of injury from bullets, intra-specific fight (in large bulls) and mauling by large carnivores (generally in case of calves). For captive elephants, look for injury inflicted by mahouts.
- Examine fresh dung dropping or collect one from the rectum. This will give indication about the teeth condition.
- Inspect the natural orifices for discharges and the oral cavity for lesions of rinderpest, foot-and-mouth disease, etc.
- Examine temporal glands for musth.

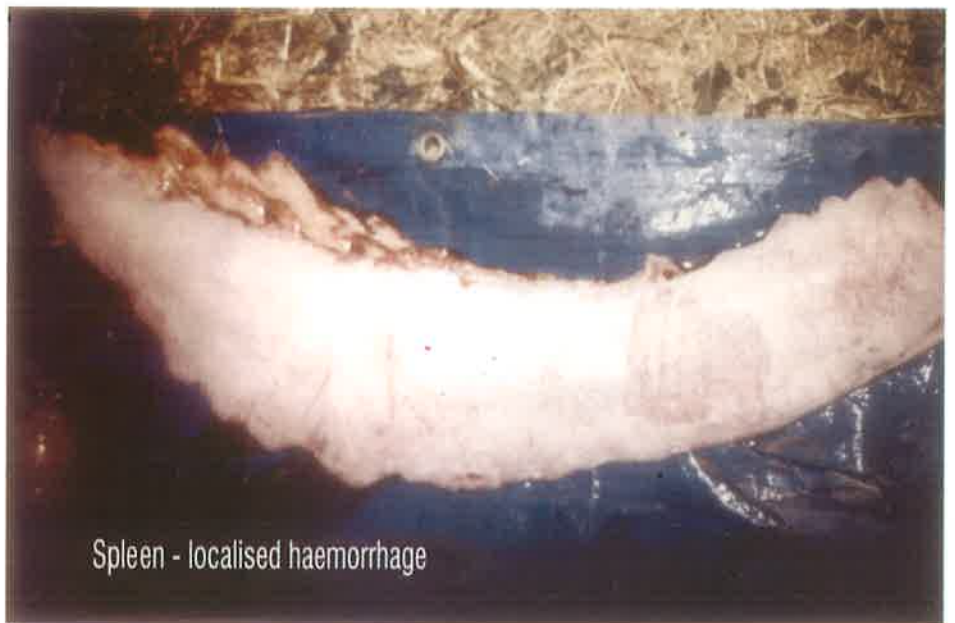3. Internal Examination

Necropsy should be conducted in a systematic manner. It is, therefore, essential to assign specific task to each of the team members. A team consisting of two or three assistants may be assigned to each of the following:

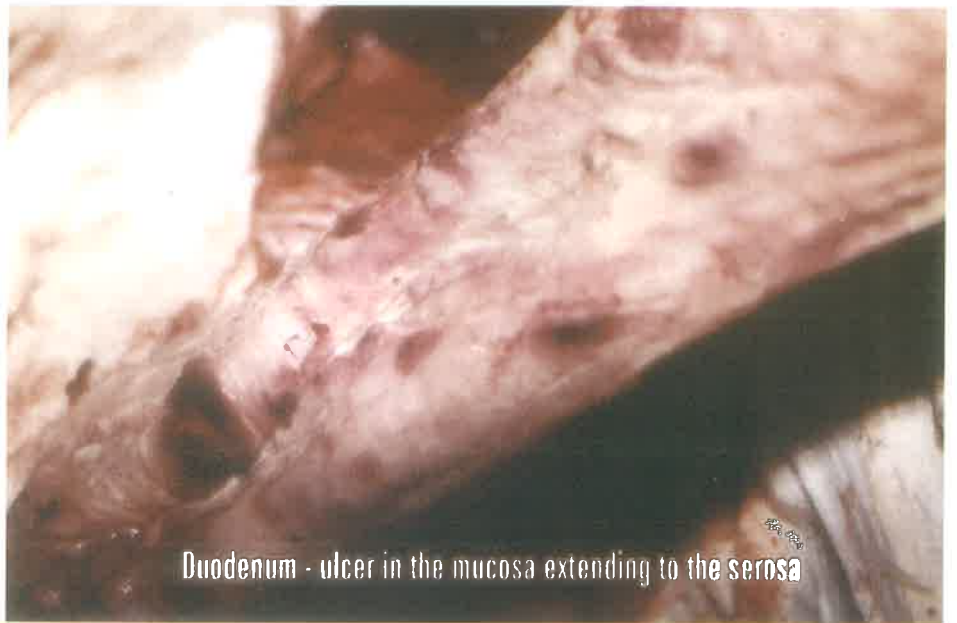- (a) Head
- (b) Fore-limbs
- (c) Hind-limbs



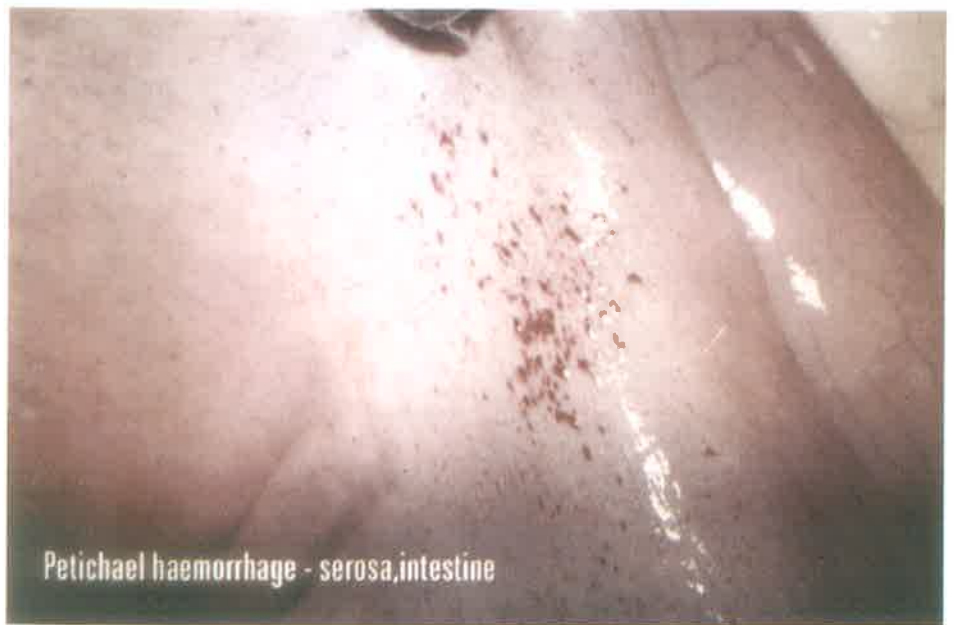Liver - sub capsular haemorrhage



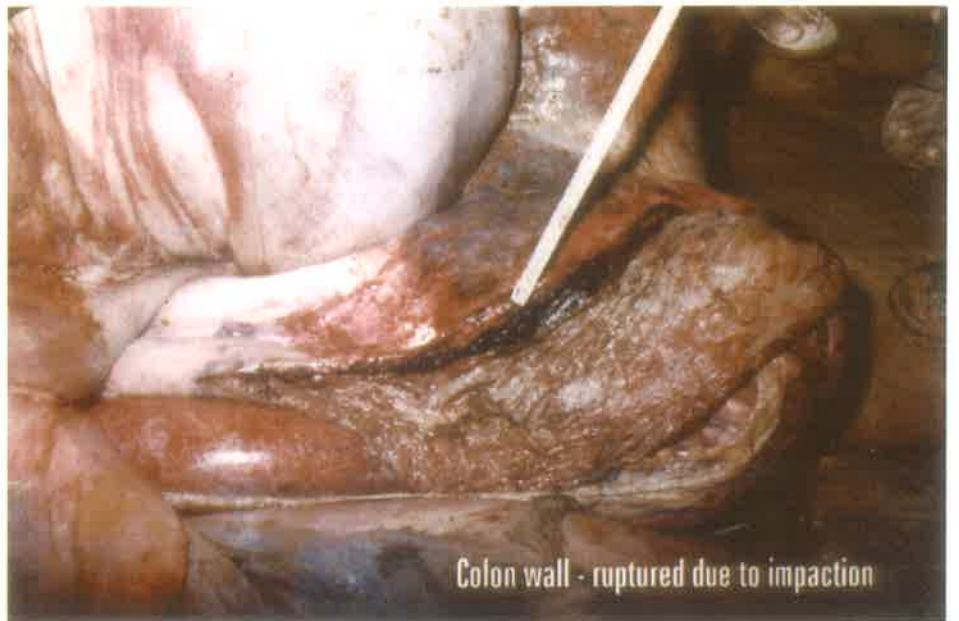
Spleen - localised haemorrhage



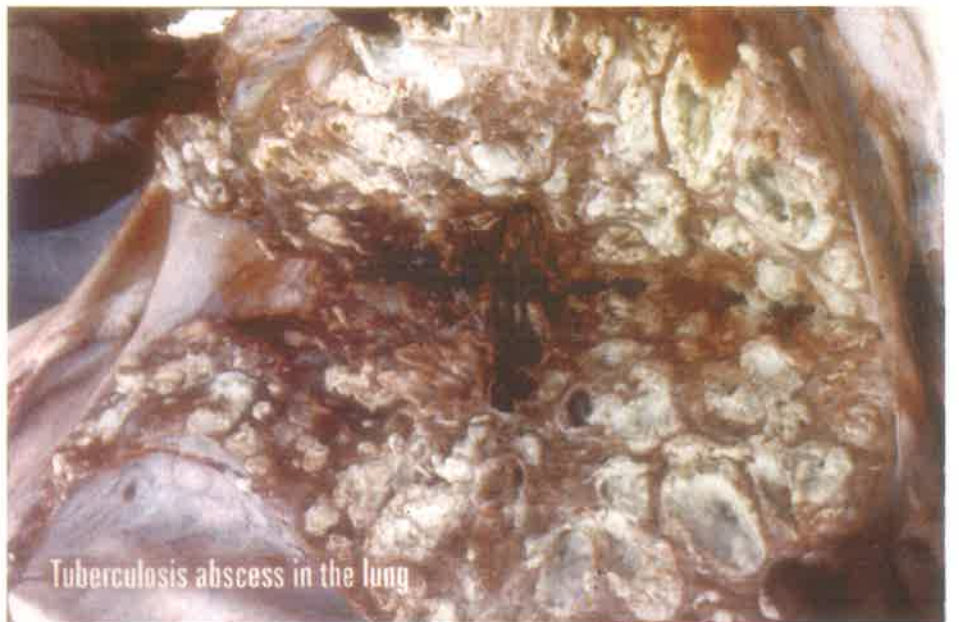Duodenum - ulcer in the mucosa extending to the serosa



Petichael haemorrhage - serosa,intestine



Colon wall - ruptured due to impaction



Tuberculosis abscess in the lung

- (d) Thoracic region
- (e) Abdominal region

Head

Dissect and remove the ears. Cut and remove the trunk at the level of the lower lip. Disarticulate the head while cutting through the atlanto-occipital joints and separate from the body. Dissect out the tusks. Several cuts are required to sever the bones to reach the base of the tusk. A good portion of the cranium must be cut to reach the brain. (Large knives, long axe, chain saw and chisels can be used for cutting.) Make three connecting deep cuts in the margins of the triangle formed at the base of the skull using an axe. Remove the bony plates by lifting them with a crowbar and expose the brain. The brain is dissected out after severing the attachments.

Fore-limbs

Disarticulate and remove the segments after cutting through the shoulder joint, elbow joint, the radio-ulnar and carpal joints. (Small axe can be used for cutting and crowbar for lifting the parts and severing the joints. Tie with rope and pull out the segments).

Hind-limbs

Remove the segments as above, after cutting through the hip joint, stifle joint, tibiofibular and tarsal joints.

Thoracic cavity

Dissect out the skin and subcutaneous tissue along the vertebral column and lift them up. Put an incision in the middle of the dissected skin; pass a rope and tie. Pulling the rope can flap the dissected structures. Separate and remove the structures by making deep incisions at the margins of the ribs at the cranial and abdominal ends of the thoracic wall and connecting them with a deep ventral mid-line incision. Cut the vertebral articulation and expose the thoracic cavity by pulling the ribs along with the muscles as above and severing it from the costo-chondral articulations of the sternum. The heart, lungs and associated structures are thus exposed and can be cut and separated.

Abdominal cavity

Dissect out the skin, subcutaneous tissue and muscles by making deep incisions along the ventral mid-line from the xiphoid to the pubis. Lift up

the structures and separate them out by putting deep incisions from pubis to the anterior border of the iliac crest and along the lumbar vertebrae. Slip off the omentum and pull out the intestine and stomach. Remove the liver and spleen separately after dissecting their attachments. The kidneys, bladder and the reproductive organs (uterus and testes) are removed by separating their attachments.

4. Examination of organs

All parts of an organ should be examined thoroughly. Emphasis should be given to differentiate lesions from post-mortem changes. Look for the following while opening the carcass and examine individual organs as detailed below.

- Actual location and orientation
- Relative size and shape
- Presence of abnormal fluid in the body cavities
- Odour emanating from the organs
- Nature of contents in hollow organs

The procedure commonly followed in the examination of some of the important organs is outlined below:

- A. Eyes:** This may be dissected out of the orbit for examination.
- B. Pericardium:** Cut open with a sharp pointed scissors. See the contents and examine the surface.
- C. Heart:** Excise the heart through cutting along the coronary groove. Examine the valves, endocardium, papillary muscles and other structures
- D. Lungs:** Cut along the course of the primary, secondary and tertiary bronchi. Make multiple slices of the organ through any suspected lesion. (Any lesion noticed in the lungs should be submitted for mycobacterial culture. Bronchial lymph nodes should be cultured for TB, even if normal in appearance.)
- E. Liver:** Slice the organ with a sharp knife to reveal the interior of the lesions. Look for *Grammocephalus* spp.

- F. Kidney:** Incise and strip off the capsule. Bisect the kidney and examine the cut surfaces. Cut the organ along a suspected lesion through any plane as described by the prosector.
- G. Spleen:** Active congestion of the spleen is observed in some acute bacterial and protozoal infections, e.g. anthrax, piroplasmiasis and trypanosomiasis. Cut into slices and examine the cut surface.
- H. Stomach:** Open the organ, wash with water and examine. Look for *Parabronema*, a spirurid worm. It can cause parasitic granulomas and focal ulceration in stomach. Maggots of *Cobboldia* as well as *Amphistomes*, *Pseudodiscus colinsi* (stomach flukes) may be present.
- I. Intestine:** Cut open longitudinally and examine the mucosa. Section through lesions and examine. Check for roundworms, tapeworms and *Amphistomes*.
- J. Lymph nodes:** Cut longitudinally and examine the cut surface.
- K. Muscles:** Make several incisions and expose the interior.
- L. Portal vessel:** It may be inspected for *Indofilaria elephantis* and *Bivetellobilharzia nairai*.

5. Collection of material

- For a specific diagnosis, histopathological, cultural and parasitological examinations should be done. Suitable materials for laboratory examination should be collected at each stage of necropsy. Heart blood, spleen, mesenteric lymph nodes should be cultured. Organs where lesions are seen and suspected for infections should also be cultured. The methods of collecting, preserving and despatching material for laboratory examination have been described in Chapter-3.
- In vetero-legal cases the tissues collected are preserved in rectified spirit or in saturated salt solution. The methods of collecting and preserving materials for toxicological examination have been described in Chapter-4.

6. Post-mortem report

An accurate recording of the lesions encountered is essential. The report

should be written in the prescribed proforma immediately after post-mortem. A descriptive account of the lesion has to be given. A model proforma is given below.

Post-mortem Report

Institution /Owner:
Address:
Post-mortem No.:
Species:_____ Age:_____ Sex:_____ Colour:_____
Wild_____ Wild caught_____ Captive born_____
Date and time of death:
Death location:
Necropsy date:_____ Time:_____
Necropsy location:

Clinical history and clinical diagnosis: (include signs, clinical laboratory data, circumstances of death, feeding, probable cause of death, suspicious state or diseases suspected by the clinician)

Blood smear examination: (It is always advisable to examine a peripheral smear before the necropsy is begun)

General findings: (include rigor mortis, condition of the carcass, approximate time of death, skin, body orifices, superficial lymph nodes)

Body cavities and sinuses: (nasal cavity, sinuses and thoracic cavity)

Respiratory system: (Nasal cavity, nasal passages, pharynx, larynx, trachea, bronchi, lungs and regional lymph nodes)

(**Note:** It is always advisable to culture the lung lesions and examine the impression smears of the lesion after acid fast staining for TB)

Cardiovascular system: (pericardial sac, heart, vessels, valves and chambers of the heart)

Digestive system: (mouth, tongue, oesophagus, Liver-GB is absent, stomach, small intestine, caecum, large intestine, rectum, omentum, mesentery and lymph nodes)

Spleen:

Urinary system: (Kidneys, ureter and bladder)

Reproductive system: (ovaries, vagina, cervix, uterus, mammary gland, testes, penis and prostate)

Musculoskeletal system: (bones, joints and muscles)

Central nervous system: (brain, meninges and spinal cord)

Endocrine system: (Thyroids, parathyroid, pancreas, adrenals and pituitary)

Additional observations in general:

Special laboratory examination conducted:

(Results of cytology, fluid analysis, urinalysis, serum chemistry, bacteriology, virology, Parasitology, histopathological findings)

Summary:

Post-mortem diagnosis:

Etiopathological diagnosis: (this can be done after evaluating the post-mortem lesions and the report of laboratory examination of materials being collected and sent during necropsy)

Post-mortem done by:

Date: _____

7. Causes of death

All death can be attributed to the failure of any one of the cardinal pillars of life: the heart, lungs and brain.

7.1. Lung failure (asphyxia):

- Face and neck cyanosed.
- Extravasations of blood beneath the conjunctiva.
- Right ventricular dilatation and filled with blood.
- Left side of the heart-contracted and empty.
- Lung congested.
- Spleen contracted.

7.2. Heart failure (syncope)

- Pale carcass
- Heart contracted and empty.

7.3. Brain failure (Coma)

- Haemorrhage in brain and infarction of brain.

7.4. Lesions in special cases

A. Electrocution

- Effect depends on the strength, duration and effectiveness of the contact.
- Death due to ventricular fibrillation and vagal inhibition.
- Electrical shock, current marks - crater like ulcers, which are resistant to decomposition.
- Endocardial haemorrhage
- Hardening of the brain
- Petechiae in serous membranes
- Anoxic changes.

B. Lightning

- Arborising tree like reddish lines, lacerations and concussion at the site of entry and exit can be seen.
- Singing of the hair.
- Brain haemorrhage and haemorrhage in the subcutaneous tissue.

C. Heat stroke

- Haemorrhages in visceral organs
- Oedema in brain
- Myocardial haemorrhage
- Pulmonary oedema

D. Gun shot

- Circular clean hole with inverted edge at the point of entry, larger hole with everted and ragged border at the subcutaneous tissue.
- Haemorrhage in the internal organs.

Chapter-3

COLLECTION, PRESERVATION AND DESPATCH OF MATERIAL FOR LABORATORY EXAMINATION*

The success of laboratory examination depends mainly on the proper collection, preservation and despatch of suitable materials. Whereas the field veterinarian can view the entire carcass and note the condition of all the organs, the laboratory technician will have to depend upon only the materials supplied to him. It is, therefore, very necessary for the field veterinarians to supply for the laboratory examination all such materials that are likely to be of value in the diagnosis. The covering letter should contain all particulars of the specimens, preservatives used, history of the case and the time of animal's death and that of necropsy. The field veterinarian should also enclose a copy of the post-mortem examination report and mention, when possible, the disease suspected and the specific tests required. For quick disposal of the material, it is advisable to forward one copy of the covering letter by post and to enclose another in the parcel containing the specimen. All possible measures should be taken for specimens to reach the laboratory in the shortest possible time after their collection.

The materials required for diagnosis and the methods to be adopted for their collection and preservation depend on several factors such as the kind of examination required, the disease under investigation, the apparatus available, the atmospheric conditions and the length of interval between collection and laboratory examination. However, the general requirements are given in the following pages.

1. SMEARS

The glass-slides used for making smears should be absolutely clean and free from grease. Standard firms supply slides for ready use. If unclean, they should be washed in water and, after they have been drained and dried, immersed in a 5% solution of hydrochloric acid in alcohol for a few

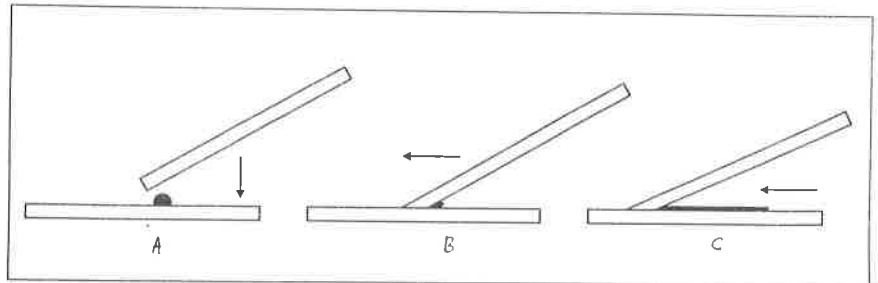
hours. The use of methylated spirit should be avoided for preparing this solution as it turns milky on contact with water. The slides should then be washed thoroughly in running water and kept in absolute alcohol or rectified spirit in a clean-stoppered bottle. When required for use, they may be removed with a pair of forceps and the alcohol burnt off by passing the slide through a flame.

Blood

Blood films for microscopic examination should be thin. It is best to collect the blood from the tip of the ear in the case of a living animal or of an animal suspected to have died of anthrax. The procedure is as follows:

1. Clip the hair from the tip of the ear, if necessary.
2. Wipe away hair and dirt from the clipped area with a little dry cotton wool. Swab with methylated spirit and let it dry.
3. In a living animal, make a puncture at the tip of the ear with a pin that has been sterilised by flaming, while in a dead animal snip out a little piece of the skin at the tip and allow the blood to ooze from the wound.
4. Bring the surface of a slide in contact with the blood droplet or transfer the droplet to this slide by means of the edge of another slide. In either case, the blood should be deposited at a point on the slide about 1 cm from one end, while the quantity of blood removed from the wound should be just sufficient to spread within the middle half of the slide, leaving the ends blank.
5. Take another clean slide with a straight smooth edge at one of its ends for use as a 'spreader'. Place this edge just in front of the drop, holding the slide firmly, at an angle of about 45° on the lower slide, which may be placed on a table or some other flat surface. Now bring the lower end of the spreader slide in contact with the drop of blood, which will spread along the end of the slide by capillary attraction. Glide forward the upper slide evenly at a uniform pace so as to spread the droplet in a thin uniform film on the surface of the lower slide (See diagram). From animals suspected to have died of anthrax thick smears should be prepared, and it may be better to make two thin and two thick smears in each case for transmission to the laboratory. While making films, the slides should be protected from the direct sunrays, especially in summer months, to avoid rapid drying of the blood and the consequent formation of artefacts.

Diagram



6. Dry the films in shade by waving them in the air.
7. In the case of films to be examined for protozoa or blood changes, immerse the slides in acetone-free methyl alcohol for about 10 minutes and then allow them to dry. Smears to be examined for bacteria should be fixed by repeatedly passing the slide, film upwards, through a flame until the glass is just uncomfortably hot when felt with the back of the hand.
8. Mark the slides with a grease pencil or fix labels on them to indicate the nature of the smears.
9. Place the slides back to back and wrap in a clean paper.
10. Enclose a brief description of the smears while packing for despatch.

Pus

Prepare a thin smear by spreading the pus evenly on a slide, with a sterile scalpel. In case this method fails to give a satisfactory smear the following procedure may be adopted:

1. Place a small quantity of the pus on the middle of a slide.
2. Place a second slide on the first one so that the pus is held between the two slides.
3. Press gently the two slides together so as to spread the pus.
4. Hold the opposite ends of the two slides in each hand and draw them apart, taking care not to lift one from the other as this will cause the formation of lumps and bubbles. If a thin smear is not obtained in the

first attempt, the slides may be placed together again and the process repeated.

5. Dry the films by waving in the air, fix over a flame, label, pack and despatch.

Secretions and excretions

1. These can be collected in clean vessels and sent under refrigeration to the laboratory for detailed examination. It is always better to have a styrofoam (Thermocol) box filled with ice to carry the various biological materials for culture and isolation of organism and for sero-diagnosis.
2. The discharge can also be preserved using 10% neutral formalin. 2 or 3 ml of this solution will be sufficient for 3-5 ml of discharge.
3. Smears can also be immediately prepared from the discharges in clean slides and fixed rapidly by heat. These should be wrapped properly and kept.
4. For oozing lesions and cavities containing pus or other materials (as often seen in TB of lungs) – a small drop may be collected in a clean slide and uniformly spread using a tooth pick or swab and fixed immediately in heat.
5. In suspected cases of TB it is better to have material scraped out from the lesions (after evacuating the contaminated pus) collected on a clean slide and fixed.

Tissue

Tissue smears should be prepared as follows:

1. Cut out a small piece of the organ, hold it in a pair of forceps and rub its cut surface on the middle third of the slide.
2. If fluid accumulates on the cut surface, transfer a very small quantity of the fluid to a slide with a sterile scalpel and then spread it.
3. If the cut surface is very dry, scrape it with a sterile scalpel and spread the scraping evenly on a slide. This may be done with the help of normal saline, if necessary.
4. Caseating nodular and calcified lesions may be treated in the manner described for pus.
5. Fix and despatch as directed for blood smears.

(Note: Please also refer to Appendix-I for further details).

2. BLOOD AND BLOOD SERUM

Blood Serum

1. Select the appropriate vein of the ear and clean the skin with anaesthetic ether or methylated spirit.
2. Insert a sharp, large-bore, hypodermic needle into the vein and collect the blood directly into a round, screw-capped, wide-mouthed bottle of about 30-ml capacity. The needle and the bottle should be perfectly clean, sterile and dry. If on account of recent sterilisation, the needle or the bottle shows some moisture on it, rinse it thoroughly with physiological salt solution (0.9 g of sodium chloride in 100 ml of boiled water) to prevent haemolysis. A separate needle should preferably be used for each animal. But if this is not possible, the needle should be thoroughly washed out with the saline each time it is used for bleeding.
3. Do not fill the bottle more than half; set it gently on its side at an angle of 20° to the horizontal in a cool place on the premises where the blood has been drawn. Care should be taken to avoid agitation of the blood after collection.
4. When complete clotting has taken place, twist the bottle gently on its long axis through 180° . It generally takes 2 to 6 hours for the serum to separate.
5. Pipette the serum with sterile precautions into screw-capped or well-stoppered strong vials with mouths wide enough to admit a 1 ml graduated pipette.
6. Label the serum containers, pack and despatch.

If drawn properly, the serum is clear and free from blood cells or haemoglobin. A haemolysed serum sample is unsuitable for laboratory examination.

Collection with Pasteur Pipette

The collection with Pasteur pipette should be made as follows:

1. Smear with a hot spatula the surface of the organ from which material is to be collected.
2. Pass the capillary portion of the pipette several times through a flame to sterilise its external surface and allow it to cool.

3. Break gently the capillary end of the pipette with forceps, the broader end of the pipette having been fitted with a rubber teat.
4. Insert the sterilised end of the pipette into the tissue at the smeared spot, with the rubber teat kept pressed between the forefinger and the thumb. Relax the pressure on the rubber teat and draw the material into the pipette.
5. Hold the pipette at a slant so as to allow the fluid in the capillary to recede from the end. Seal the end.
6. Remove the teat from the pipette and seal the teat-end after removing the cotton plug. Continue to hold this point in the flame until the glass melts and forms a thick bead.
7. Hold the pipette with the hot end uppermost until quite cool.
8. When cooled, invert the pipette, so as to allow the fluid to collect towards the sealed broader end. Break the capillary end and seal it.

A good source of heat is essential for sealing the pipette properly. A Bunsen flame is quite suitable for the purpose but is rarely available in the field. However, the sealing can also be effected on a spirit lamp, provided the flame is kept steady by cutting out drafts of wind.

3. MATERIAL FOR HISTOPATHOLOGICAL EXAMINATION

The material should be properly fixed when it is in a fresh condition before being despatched. The aim of fixation is to set or fix the tissues in, as normal a condition as possible and to prevent post-mortem changes in them. Once the putrefactive or autolytic changes have set in, the tissues become unfit for histopathological examination, for they cease to represent the structures they had at the time of death. The following procedure is recommended for fixing tissues:

Use a fixative that would penetrate and kill the tissue cells before these have altered by autolytic or other changes. The quantity of the fixing solution used should not be less than 10 times the volume of the material. Cut the tissue into thin sections, each around 0.5 cm in thickness so that the fixative may penetrate and kill the cells quickly. In case it becomes necessary to send a large mass of material for examination, it should be accompanied

by some small slices of the organ or lesion cut out and fixed separately. The most commonly employed fixing reagent for general histological work is a 10% solution of formalin in normal saline, which not only fixes the tissues in 48 hours but also preserves them.

To avoid bulk in transit, the material, after proper fixation, may be transferred to a smaller bottle containing a sufficient quantity of the preservative to cover the tissues. A layer of absorbent cotton wool should be placed over the material and also at the bottom of the container to prevent damage to the tissues by jolting during transit. The material selected for despatch should comprise representative portions of the lesions as well as portions of the apparently healthy tissues surrounding the diseased area. The material that is likely to yield the most useful information concerning the pathology of the condition under investigation is usually the youngest portion of the lesion at the junction of the diseased and healthy tissues. Sections taken only from the centre of a large lesion are apt to be misleading.

4. MATERIAL FOR CULTURAL EXAMINATION

The material must be collected with aseptic precautions and dispatched in sterile containers to prevent contamination from extraneous sources. In the case of dead animals, the specimens should be taken soon after death, for otherwise putrefactive bacteria invade the tissues and render them unsuitable for examination.

Solid tissues such as liver, spleen and kidney, may be forwarded, if fresh, without a preservative, on ice, when the examination is to be carried out within a short time of their collection. If however, the examination is to be delayed by a few days, it is preferable, especially in summer months, to preserve the tissues in a 25% glycerine saline. While forwarding the material in this preservative, it would be better also to send larger pieces of the tissues, so that, if necessary, cultures may be attempted from their central areas where the glycerine has penetrated the least.

Liquid material such as inflammatory exudates, heart blood and cerebrospinal fluid may be taken either in sterile swabs or sealed in pipettes.

When large quantities of the material are required for laboratory examination, they should be removed from the body with sterile pipettes and collected in tubes or bottles, with strict aseptic precautions throughout the procedure. If peritoneal fluid is required, an area on the abdominal wall is seared thoroughly with a hot spatula and a sterile forceps is used for holding the cavity open and sterile pipettes for drawing the fluid. Similarly, for collecting heart blood, the surface of the organ should be well seared and a sterile pipette inserted into it for drawing the blood.

For taking swabs of the contents of a closed abscess in an animal, clip the hair from the area and paint it with tincture of iodine. Open the abscess with a sterile scalpel and take swabs from the wall as well as from the contents of the abscess and keep the swabs in sterile tubes.

To collect wound discharge, the wound should be thoroughly cleaned with warm water and soap, and sterile non-antiseptic cotton wool or gauze dressing applied. The material should be collected after about 24 hours by inserting a sterile swab underneath the dressing. This is usually done in living animals.

5. VIRUS MATERIAL

Virus material for examination may be forwarded in 50% glycerol saline, or preferably in a medium containing equal parts of pure glycerol and M/25 buffered phosphate. As the viruses are generally short-lived, it is particularly important that the material should reach the laboratory in the shortest possible time after collection, preferably over ice in a thermos flask.

Preparation of 50% glycerol in phosphate-buffered saline (PBS) pH 7.5

1. Put the following chemicals in a flask

NaCl	8.00 g
KCl	0.20 g
KH ₂ PO ₄	0.12 g
Na ₂ HPO ₄ (anhydrous)	0.91 g

2. Add distilled water to 1,000 ml
3. The PBS solution may be sterilised by autoclaving at 8-kg pressure for 35 minutes.
4. Add equal quantities of PBS and glycerol. The glycerol should be of analytical reagent grade and neutral. Prior to its being added to PBS, it should be autoclaved at 5-kg pressure for 10 minutes.

Scabs from pock diseases may be forwarded in a dry specimen tube without the addition of preservative.

6. PARASITIC MATERIAL

Specimens of Insects, Ticks and Free living Mites

Winged specimens should be killed with chloroform in a cyanide-killing bottle and pinned in entomological store-boxes or on the under side of the cork inside a specimen tube. Specimens of ticks, mites, eggs and larvae of insects may be sent in 70% alcohol. However, in case ticks and mites are engorged with blood, the abdomen may be punctured with a needle and the parasite boiled in 10% sodium hydroxide to remove the blood and soft tissues.

Mange Mites

Scrapings from mangy skin should be forwarded in dry containers sealed properly to prevent mites from crawling out. The following procedure is recommended for collection of mange scrapings:

1. Select an area where the skin lesions are most marked. In cases of very light infection, the area where the animal likes being scratched is likely to yield the most suitable material for examination.
2. Clip the hair from the selected area and moisten it with 10% solution of caustic potash or even plain water.
3. Scrape the area with a blunt knife. A sharp scalpel should not be used, for it may cut the skin.
4. Collect all loose scabs, scurf, hair etc. in a large test-tube. The scraping should be continued until blood oozes from the scraped area as it is only when this stage is reached that the area is likely to yield samples of the different forms of mites harboured by it. Each time a little quantity

- of blood collects on the scalpel, lightly scrape an adjacent area with it to cover up the blood with scurf and loose hair.
5. Wipe the scalpel against the inner rim of the tube and then detach the adherent mass with the knife to make it drop down into the tube. The blood will thus be prevented from adhering to the knife or to the mouth of the tube.
 6. Scrapings at least sufficient in quantity to cover a rupee coin should be collected from all cases suspected for mange. Negative findings are sometimes due to insufficient or only superficial scrapings having been examined for the presence of mites.

Helminths

The alimentary canal is best examined for the presence of helminths by mixing the contents of its different parts with water; allowing it to stand for 10-25 minutes, decanting away the supernatant fluid and making a careful search for the parasites in the sediment. For examination of liver and lungs, give these organs several cuts and squeeze the tissue in a basin of water to liberate the parasites, if any. The parasites may then be picked up with a pair of fine forceps. The subsequent procedure should be as follows:

1. After collection, wash the parasites quickly in 0.9% saline.
2. For fixing, transfer to steaming 5% formalin, not less than 10 times the quantity of the parasites. Glycerol may be added at the rate of 5% for keeping the worms soft.
3. Transfer after 24 hours to a smaller quantity of the fixing fluid or 70% ethyl alcohol for despatch.

For preservation of faeces containing helminths, the faecal matter, if not already thin, may be brought to the consistency of porridge by the addition of water. Bring it to boil and add 10 times its volume of 5% formalin. Mix well and let it stand. Decant off the supernatant fluid and preserve the sediment in cold 5% formalin.

Filarioid worms are very liable to burst and as such should be placed immediately in a 10% solution of formalin without washing in saline, unless they are soiled with blood.

It is difficult to remove nematode larvae or small adult nematodes which are in tissues. However, by placing the tissues in a dish of warm physiological saline, one can usually get those freed. The cestodes should be collected along with their heads as this would be of great help in proper identification. In case the heads are attached to the intestinal wall, a piece of the intestine should be cut and placed into a dish of warm water at about 40°C. The worms usually die fully extended in about an hour and the heads get free. If not, these might be dissected out.

DIRECTIONS FOR DESPATCHING PATHOLOGICAL MATERIAL BY POST

Postal regulations for despatch of pathological material should be strictly observed. The mouths of containers should be well sealed with molten paraffin wax, after securing the stoppers properly on to them with strong twine. Bottles or tubes containing dry material may be closed tightly with cotton-wool plug and the mouths then paraffined.

All containers should be properly labelled, wrapped in packing paper and packed in sufficient quantity of some absorbent material such as sawdust or cotton wool. The packing should be such as to prevent any possibility of the containers rocking in transit and also to provide for the complete absorption of fluids by the packing material in the event of breakage. All parcels should be conspicuously marked with waterproof marking pen '**Fragile—With Care**' and bear the words '**Pathological Specimen**'.

A packing note should invariably be enclosed in each parcel to indicate the nature of the specimen and the examination required, and should also give the name and address of the sender. The outer wrapper of the packing should bear a note of caution when the specimen is one of infectious material.

Chapter-4

COLLECTION AND PRESERVATION OF MATERIAL FOR TOXICOLOGICAL EXAMINATION

Some points to remember

1. A successful toxicological examination requires appropriate specimens and a thorough history, including clinical signs, treatment, necropsy findings and circumstances involved. If a known poison is suspected, a specific analysis should always be requested.
2. In all vetero-legal cases, an accurate record of all the persons keeping the custody of the material from the time of collection of sample till the final analysis in the laboratory should be maintained.
3. If feed or water is suspected as the source of poisoning, samples of these and any descriptive feed tag should accompany the tissue specimen. A representative feed sample should be submitted from the lot involved in the poisoning.
4. Specimens should be packed individually. Containers must be labelled with all information necessary to identify the specimen, and if mailed, must confirm to postal regulations.
5. Specimen should be packed in glass or plastic to prevent contamination by lead in soldered joints of cans. Metal tops on jars should also be separated from the tissue by a layer of plastic or other impervious materials.
6. No preservative should be added except in the case of nitrate poisoning. If a preservative is necessary because of distance from the laboratory, packing in dry ice or ethyl alcohol (1ml/g of tissue) is advisable. But in the latter case, a specimen of the alcohol should also be sent. Ingesta and tissue should be kept separate, as diffusion is likely to occur between the two.
7. The preservation of materials is done in 50% of ethanol (1ml/g/tissue). Tissues and fluids for analysis should be as fresh as possible, kept in refrigerator or preserved chemically. Packing with ice is preferred. Adequate refrigeration is of special importance when submitting body fluids and materials for nitrate analysis, as these salts are rapidly metabolised by micro-organisms and only low or insignificant levels may be found on analysis. Refrigeration prevents microbial growth

and helps to ensure that the salts are preserved.

8. In some case, if an adequate amount of involved feed is available, some of it may be fed to experimental animals in an effort to produce the signs and lesion observed in the field cases.
9. Samples for toxicological examination should not be washed during collection as washing may lead to the dilution of the incriminating toxic material.

Materials for detection of poisons

- Materials to be collected in suspected cases of poisoning are as follows:

- (a) 1000-1500 g of stomach contents and stomach walls
- (b) 1000-1500 g of intestinal contents
- (c) 1000-1500 g of liver
- (d) 1000 g of spleen
- (e) Urine-1 litre in a separate bottle and put thymol as a preservative
- (f) Kidney-one

- In survival cases, the following materials may be sent for analysis: stomach wash, stomach contents, vomitus, blood, urine, faeces, water and feed.
- Where the poison is suspected to be consumed by inhalation, parts of small intestine with its contents, liver, one kidney, lung, heart and brain tissues must also be sent.
- Uterus and foetus may also be useful in suspected cases of abortion.
- Burnt bones ashes should be preserved for analysis, if dead body has been cremated. The skeleton or the remnant bones are important materials for analysis in cases of exhumed bodies where no visceral tissues are available for toxicological examination.

(Note: Please also refer to Appendix-II for further details).

Containers for preservation of materials

Wide-mouthed glass bottles of about 2-litre capacity having airtight stoppers should be used for visceral tissues. These bottles should be numbered and labelled properly which should mention about the details of the case, nature of the contents preserved, place and date of preservation etc., and should bear the signature of the veterinarian.

Preservation of tissues

The tissues are taken into the container and sufficient alcohol is added so that whole tissues are dipped into the solution.

Tissues are also preserved in saturated sodium chloride solution (some excess quantity of undissolved salt should remain at the bottom). Solid common salt may also be used for preservation of the post-mortem tissues. The tissues are taken into the container and sufficient quantity of common salt is added to it. The tissues are immersed well with the salt. Some salt should remain at the bottom of the container and over the tissues.

A sample of alcohol or saturated solution of common salt used for preservation must also be sent in separate glass bottles for analysis to exclude the presence of any poison in it.

Preservation of blood sample

The following preservation may be used for preservation of blood sample:

1. Sodium fluoride 20 mg/ml of blood
2. Solution containing 10 g of sodium citrate and 200 mg of mercuric chloride dissolved in 100 ml of distilled water. One drop of this solution is sufficient for each ml of blood. The appropriate amount of fluid is taken into the clean dry glass bottle; the fluid is dried so that the salt remains sticking in the bottle. Then bottles are cooled at room temperature and the sample of blood to be preserved is taken into these bottles.

Appendix-I

CHECK LIST FOR FIXED TISSUES*

All tissues listed below should be preserved in 10% buffered formalin (one part by volume of tissues to 10 parts by volume of fixative). Tissue-samples should not be thicker than 0.5 cm. A sample of all lesions seen and of all listed tissues should be included.

Tissues

Salivary glands

Oral and pharyngeal mucosae

Tonsil

Tongue (cut across tip)

Trachea

Lungs (specimens from several lobes)

Thyroid and parathyroid glands

All major lymph nodes (sectioned to one-cm cube)

Thymus

Heart (sections from auricles, ventricles and valves)

Liver (3 representative specimens and duct)

Spleen (representative cross section with capsule)

Oesophagus (representative section - 3 cm)

Stomach (several specimens from all areas)

Intestines (3 cm representative specimen from each region)

Omentum (specimen of 3 cm)

Adrenal glands (if possible whole incised or cut in half)

Kidney (one- cm cube cortex and medulla of each kidney]

Urinary bladder (ureters, urethra, cross section of bladder including mucosa; 3-cm sections of ureters and urethra)

Uterus and Ovaries (if possible complete with ovaries, incise horns to allow entry of fixatives) being too big representative samples of cervix,

uterine wall and ovaries cut transversely

Testes (0.5 cm cube section of each with capsule)

Epididymis (representative sample)

Prostate gland (representative one- cm cube)

Eyes (whole eye, incise sclera to allow entry of fixative)

Brain (cut in half and part preserved in formalin and the other preserved for virology and toxicology)

Spinal cord (sections from cervical, thoracic and lumbar)

Diaphragm and skeletal muscles (representative samples)

Bones (sections sawn)

Skin (sections of abdomen, lip and ear pinna)

Neonates (umbilical stump and surrounding tissue)

Appendix-II
GUIDELINE FOR SUBMITTING SPECIMENS FOR
TOXICOLOGICAL EXAMINATION *

Suspected Xenobiotic for Analysis	Specimen Required	Amount Required	Remarks
Ammonia/Urea	Whole Blood or Serum Urine Rumen contents	5 ml. 5 ml. 100 g.	Frozen or may add 1-2 drops of saturated mercuric chloride
Arsenic	Liver, Kidney Whole Blood Urine Ingesta Feed	100 g. 15 ml. 50 ml. 100 g. 1-2 kg.	
Chlorinated Hydrocarbons	Cerebrum, Ingesta Fat Liver, Kidney	100 g.	Use only glass containers. Avoid aluminium foil for wrapping specimen.
Copper	Kidney, Liver Serum Whole Blood Feed Faeces	100 g. 2-5 ml. 10 ml. 1-2 kg. 100g.	
Cyanide	Forage Whole Blood Liver	1-2 kg. 10 ml. 100 g.	Rush sample to laboratory. Frozen in airtight container.
Fluoride	Bone Water Forage Urine	20 g. 100 ml. 100 g. 50 ml.	Ideal sample will be the lesion seen in teeth and done.

Contd.....

Herbicides	Treated weeds Urine Ingesta Liver, Kidney	1-2 kg. 50 ml. 500 g. 100 g.	
Lead, Mercury	Kidney Whole Blood Liver Urine	100 g. 10 ml. 100 g. 15 ml.	Heparinized, do not use EDTA
Mycotoxins	Brain, Forages, Liver, Kidney	100 g.	Airtight container, plastic bag. For dry feeds—cloth bags.
Nitrate	Forage Water Body fluids	1-2 kg. 100 ml. 10-20 ml.	
Organophosphates Organocarbonates	Feed Ingesta Liver Urine	100 g. 100 g. 100 g. 50 ml.	
Oxalates	Fresh forage Kidney	100 g. 100 g.	Fixed in formalin
Sodium (NaCl)	Brain Serum CSF Feed	100 g. 2 ml. 1 ml. 1-2 kg.	
Zinc phosphide	Liver, Kidney, Gastric content	100 g.	

Appendix-III
ESTIMATING THE AGE OF ELEPHANTS*

Molar	Appearance at age	Replacement age
1	4 months	2-2½ years
2	6 months	6 years
3	3 years	9 years
4	6 years	25 years
5	20 years	45-50 years
6	40 years	Lasts up to 80 years

NUMBER OF LAMELLAE PER TOOTH*

Sequential number of tooth	Asian Elephant	African Elephant
	<u>Maxillary teeth</u> <u>Mandibular teeth</u>	
I	<u>4-5</u>	<u>3-5</u>
	5	3-5
II	<u>7-8</u>	<u>5-8</u>
	6-9	5-8
III	<u>11-15</u>	<u>7-10</u>
	11-14	7-10
IV	<u>14-17</u>	<u>6-10</u>
	14-17	6-10
V	<u>17-21</u>	<u>7-12</u>
	16-21	7-12
VI	<u>20-26</u>	<u>8-14</u>
	21-29	8-14

Before the eruption as well as in the embryonic stage the plates are loose and can be separated.

Appendix-IV

METAL DETECTOR*

Deep Search Metal Detector

Deep Search Model is used for detecting ferrous & non-ferrous metal underground. It also has applications in Engineering, such as mining geology and surveying. It is also ideal for forensic use.

Sensing distance up to 1 meter.

Audio-visual indication.

Large search head-280mm diameter.

Appendix-5

SUPPLEMENTARY READING

1. Getty, R. (Ed.) (1975): Sisson and Grossman's The Anatomy of Domestic Animals. W.B. Saunders Co., Philadelphia.
2. Lokeshwar, R. (1997): Handbook of Animal Husbandry. Second edition. Indian Council for Agricultural Research. New Delhi.
3. Mariappa, D. (1986): Anatomy and Histology of the Indian Elephant. Indira Publishing House, Michigan. 48325-0456, USA.
4. Mikota, S.K., Sargent, E.L., and Ranglack, G.S. (1994): Medical Management of the Elephant. Indira Publishing House, Michigan, 48325-0456, USA.
5. Procedures for monitoring Wildlife Health and Investigating Diseases – A Field Guide (Technical report No. 3). Wildlife Institute of India, Dehradun.
6. Roth. V.L. and Shoshani, J., (1988): Dental identification and age identification of *Elephas maximus*, *J. Zool, Lond.*, 214 (4), p. 567-568.
7. Shimizu, Y., Fujita, T. and Kamiya, T. (1960): Anatomy of the female Indian elephant with special reference to its visceral organs, *Acta Anat Nippon*, 35(3), p. 261-301.
8. Shindo, T. and Mori, M. (1956): Musculature of the Indian elephant. Part 1. Musculature of the forelimb. *Okajimas Folia Anat Japonica*, 28:89-113.
9. Shoshani, J. (1994): Skeletal and other basic anatomical features of elephants. In: Proboscidea: Evolution and paleoecology of elephants and their relatives. Shoshani, J. & Tassy, P. (eds). Oxford University Press.
10. Shoshani, J., *et al* (1982): On the dissection of a female Asian elephant (*Elephas maximus maximus*, Linnaeus, 1758) and data from other elephants. *Elephant*, 2 (1):3-93.

11. Venugopalan, K. (2001): Lecture Notes on Toxicology. Kerala Agricultural University, Trichur (India).
12. Vijayan, N. and Divakaran Nair, N.: Autopsy in elephants. *Journal of Indian Veterinary Association* (Kerala Chapter), Vol. 7, No. 3, p-53.
13. Woodford, M.H., Keet, D.F. and Bengis, R.G. (2000): Post-mortem Procedures for Wildlife Veterinarians and Field Biologists. Office International des Epizooties, Care for the Wild International and IUCN.